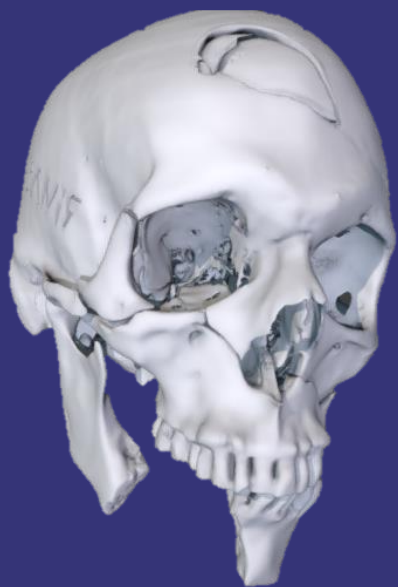
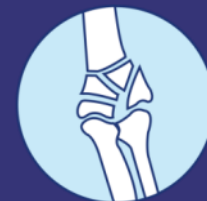
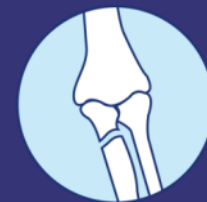

CMF



Realistic fractures with closed soft tissue

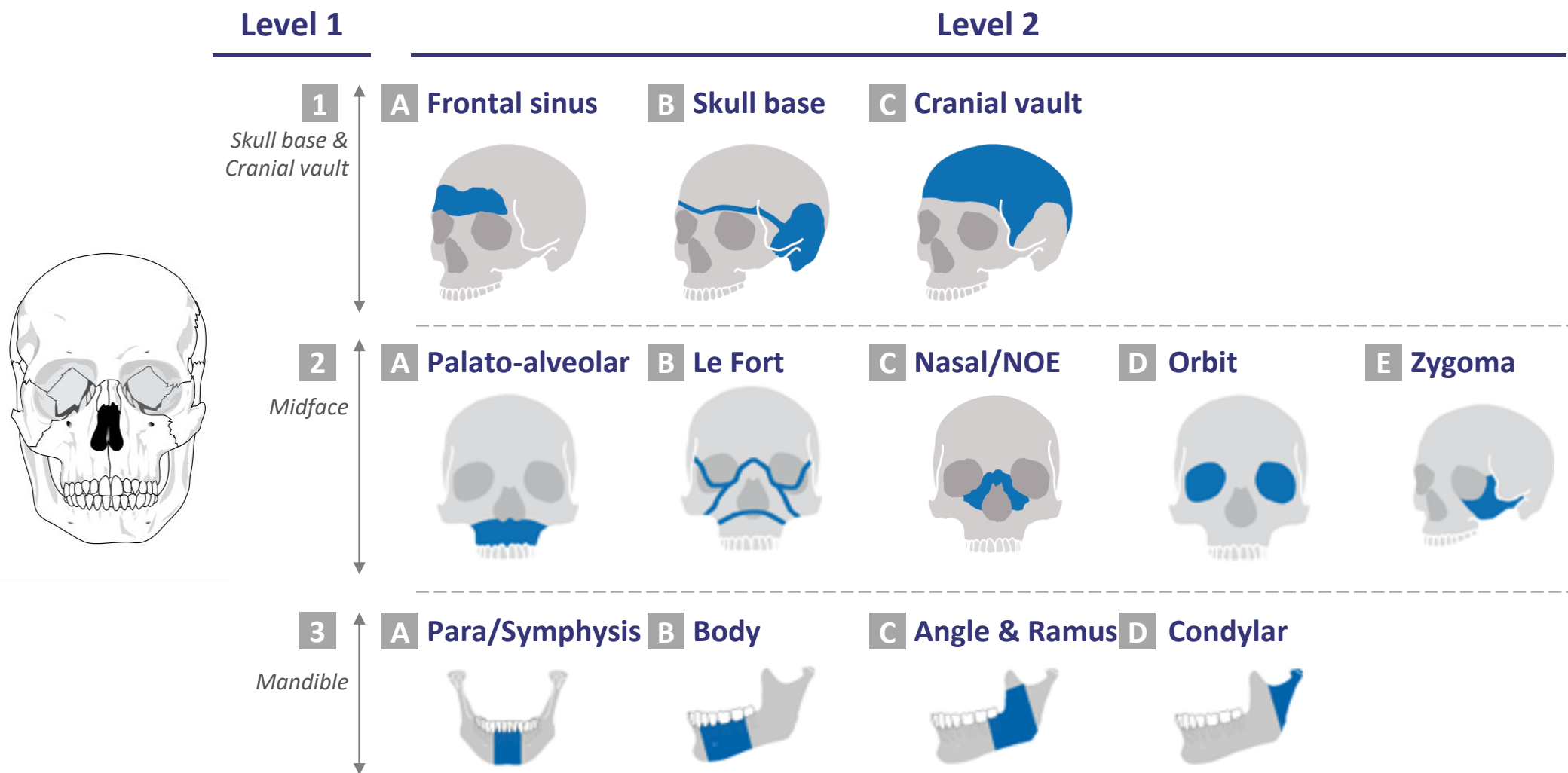
Selected examples to showcase CMF fracture portfolio

July, 2018

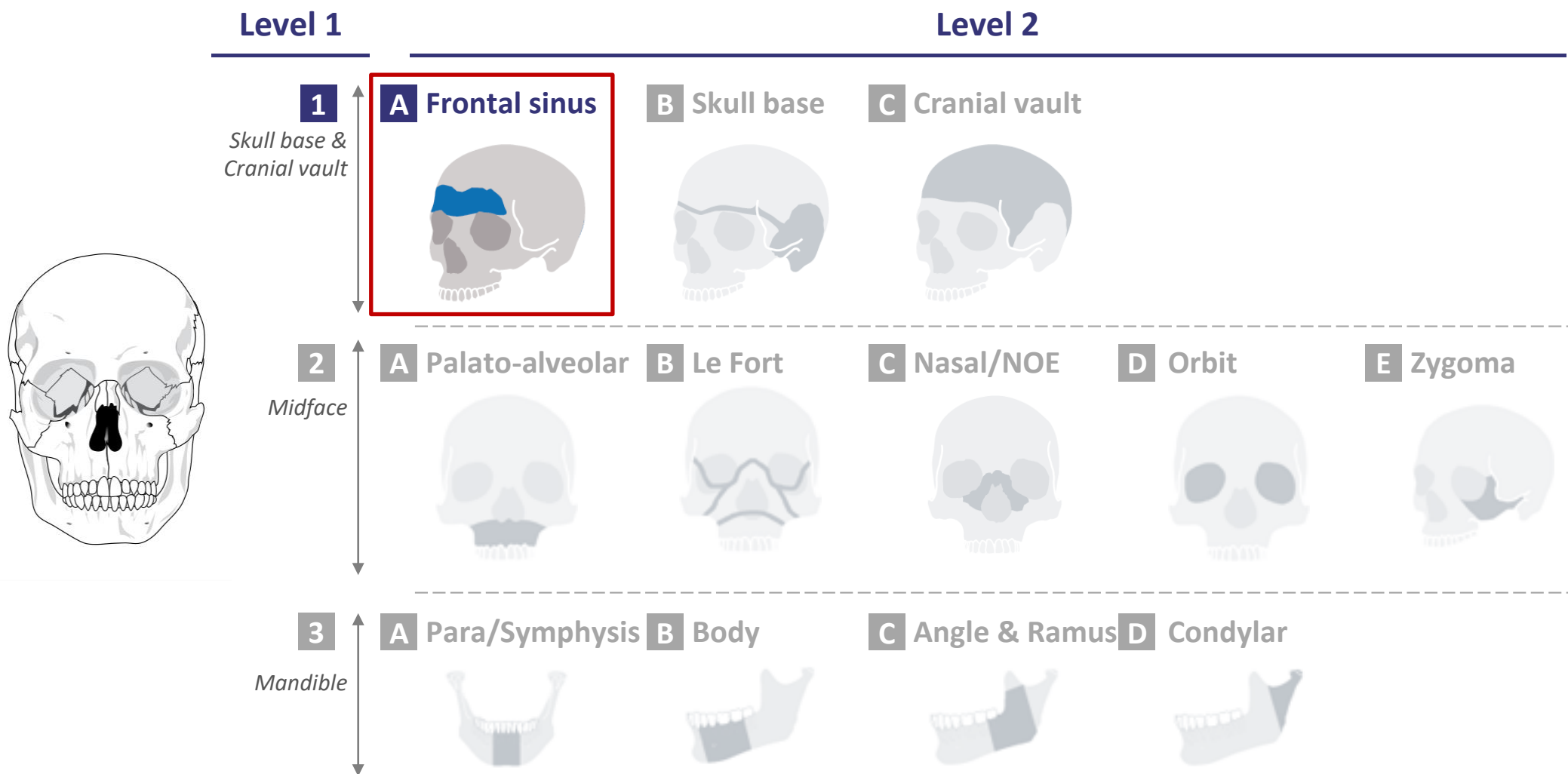
Objectives of this document

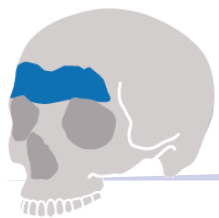- **Objective** of this document is to **outline RIMASYS CMF fracture portfolio** as basis for individual discussions and fracture ordering. All fractures in this document were generated by RIMASYS in **fresh-frozen human specimen** with **closed soft tissue**.
- Fractures can be ordered by **L1 location → L2 location → fracture complexity**
- **Classification** of the fracture portfolio is based on **three levels of complexity**:
 - “Moderate” – “single line, non-displaced”
 - “Advanced” – “multiple lines, non-displaced”
 - “Master” – “fragmented, displaced”
- Other fractures and **fracture combinations** e.g., Le Fort I + II **are available on request**

CMF fracture portfolio - logic



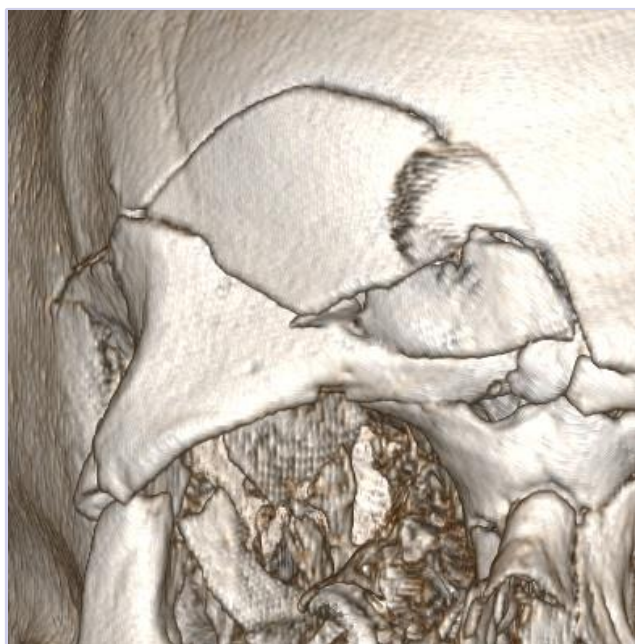CMF fracture portfolio: 1A-Frontal Sinus





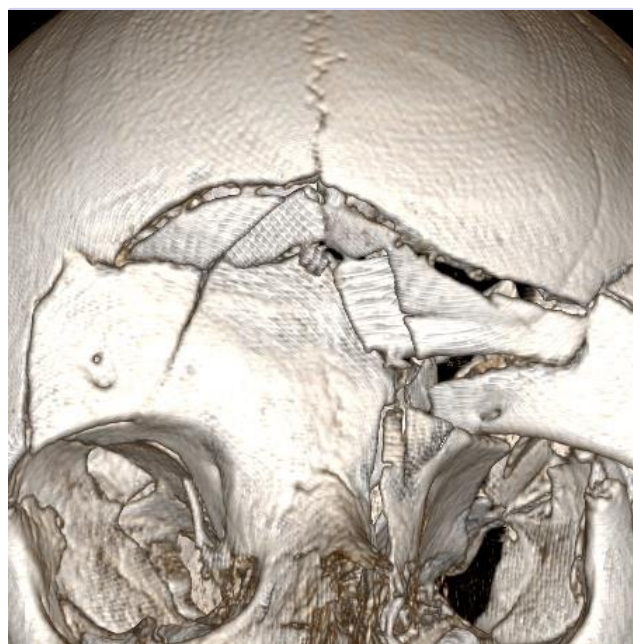
level of complexity

Moderate



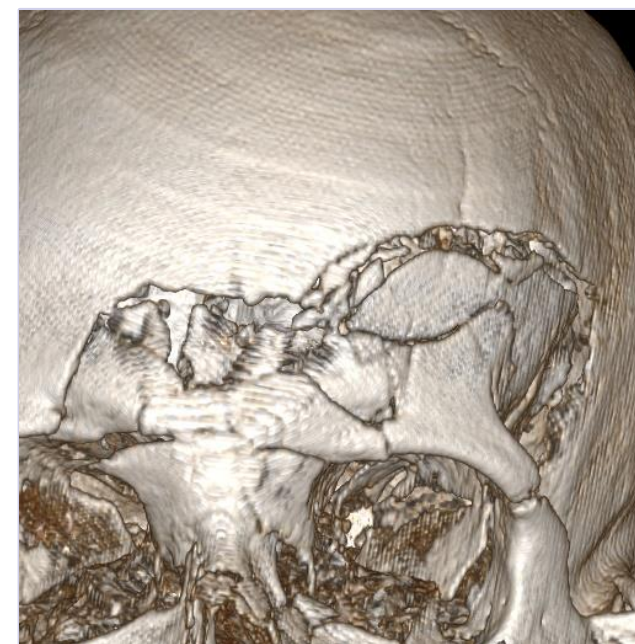- Example: F180604

Advanced

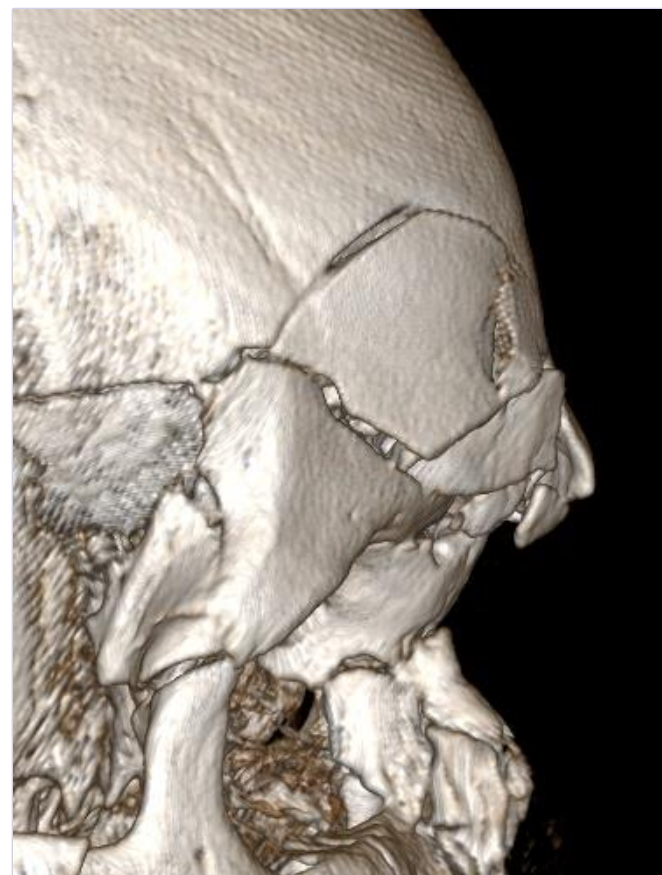
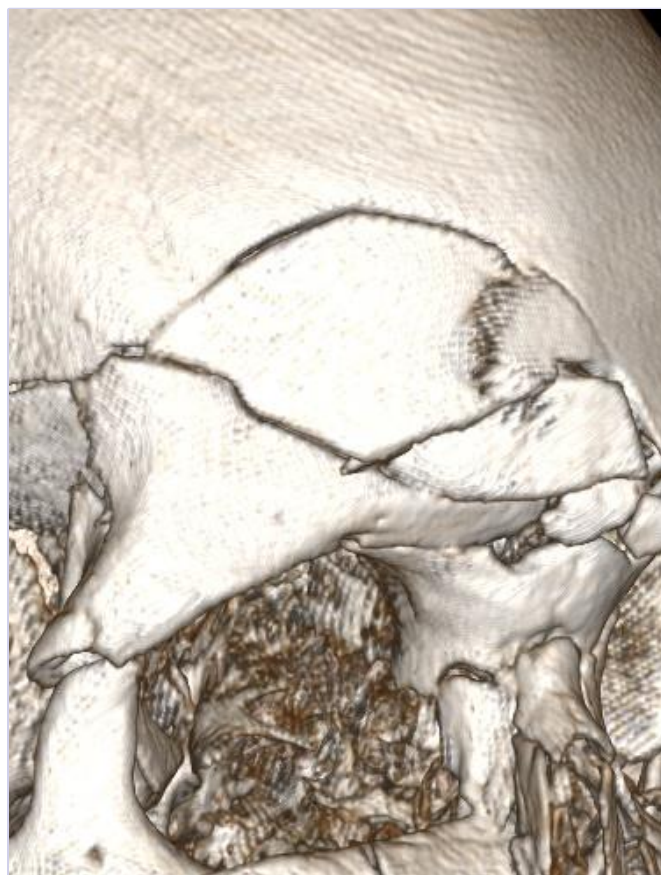
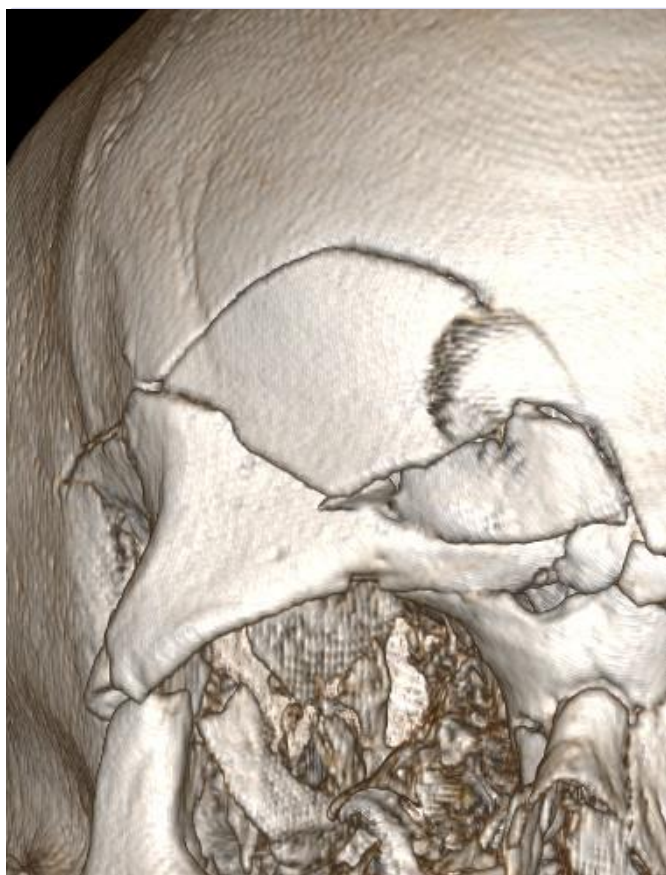
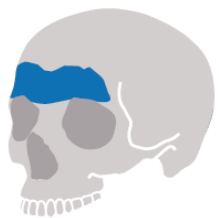- Example: F180616

Master



- Example: F180647

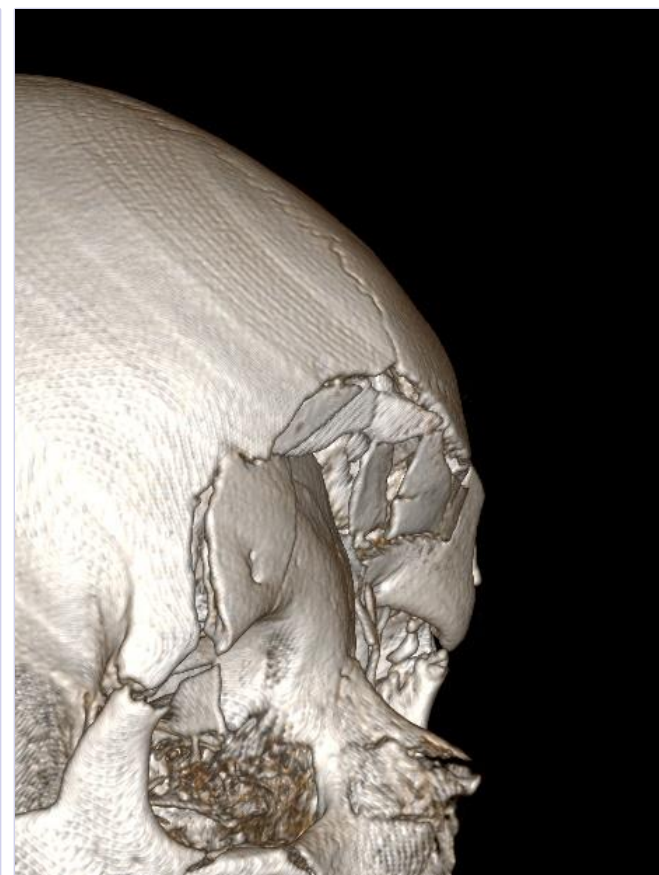
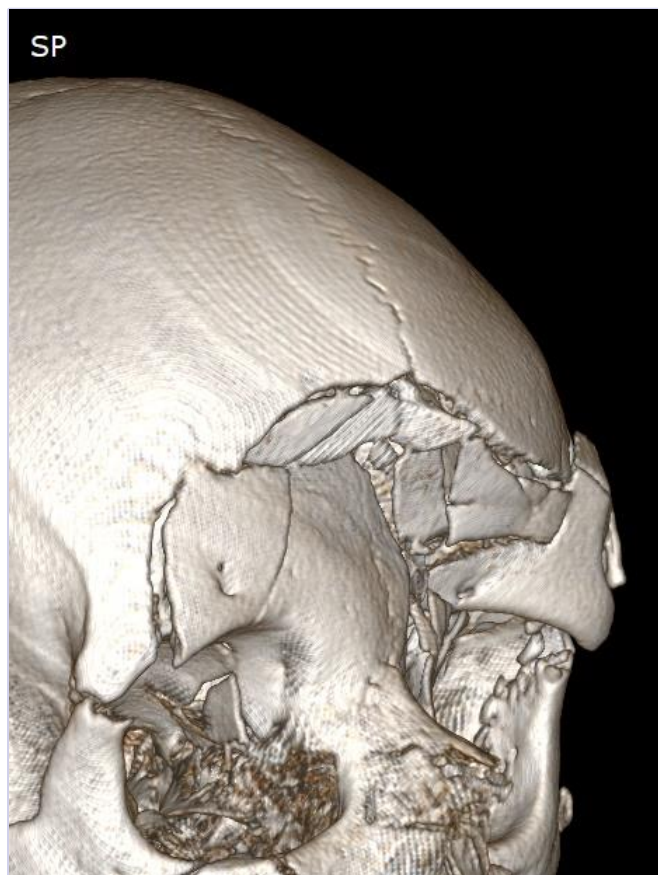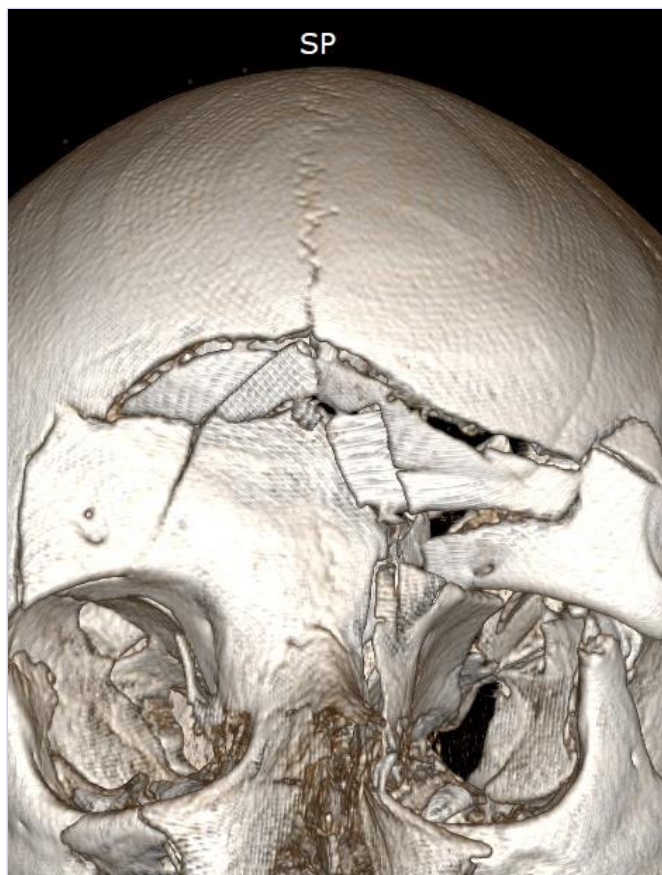


Sex: m

Age: 76

BMI: 23

18/07/2018

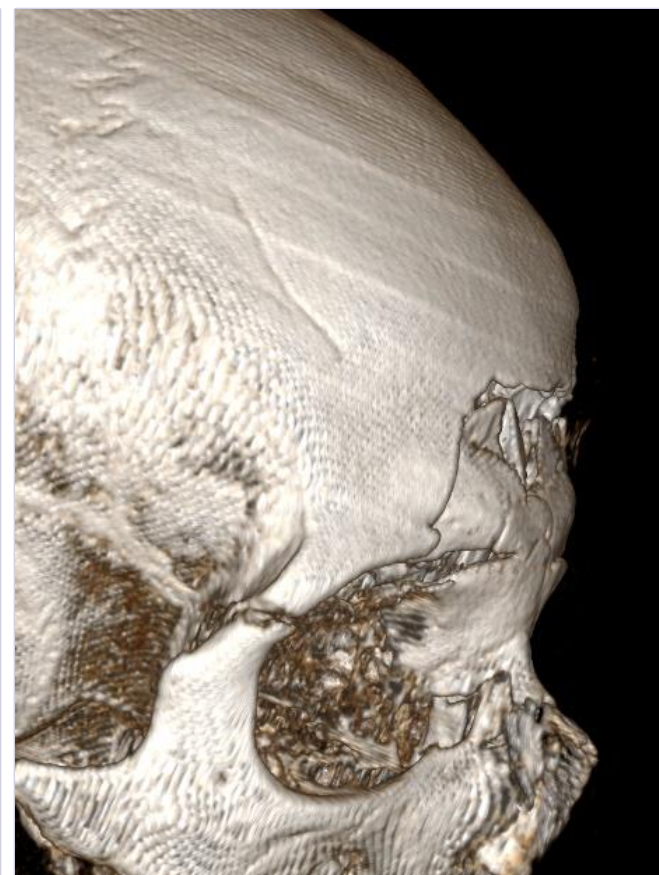
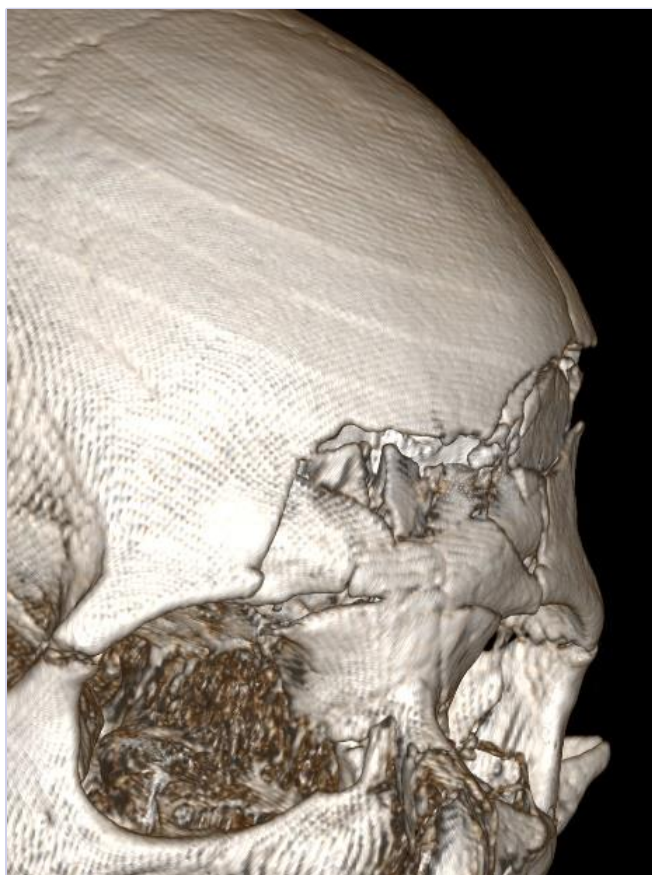
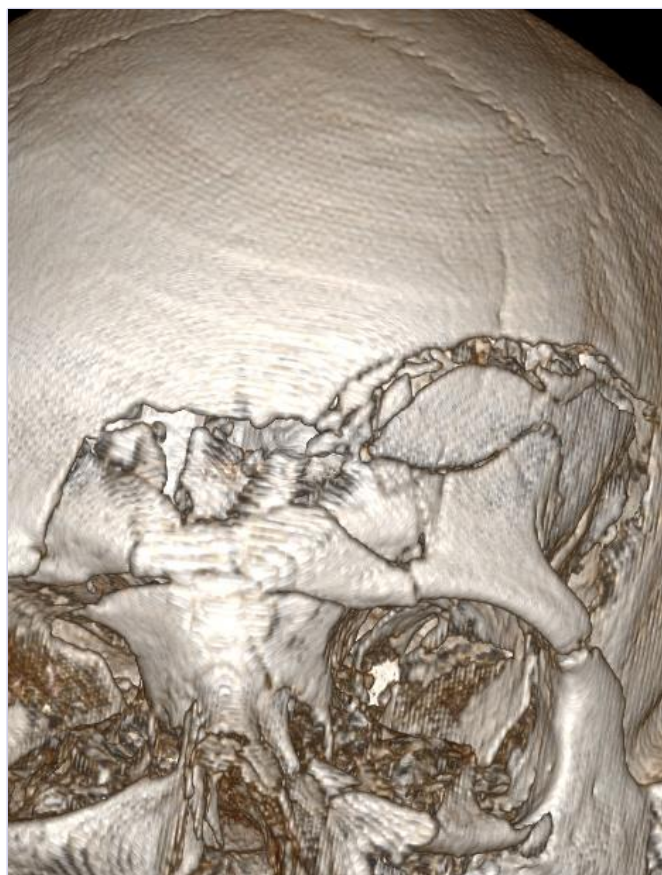

Sex: f

Age: 71

BMI: 20

18/07/2018



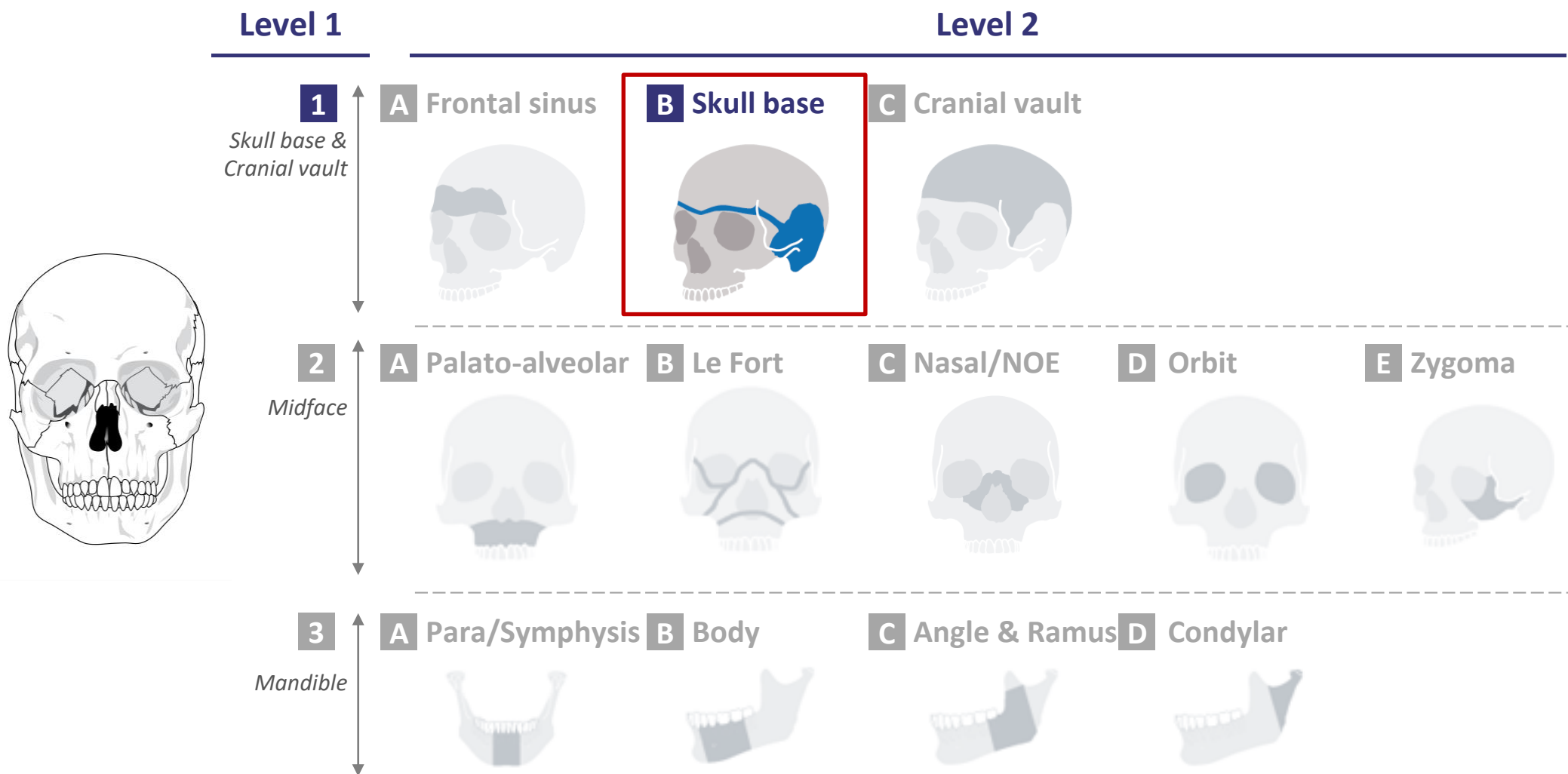
Sex: f

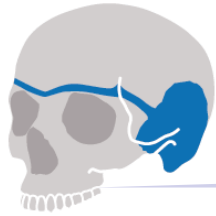Age: 80

BMI: 23

18/07/2018

CMF fracture portfolio: 1B-Skull Base



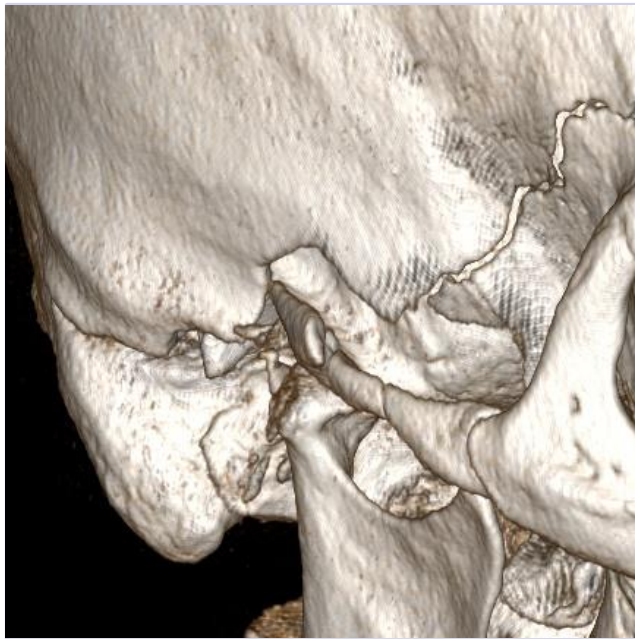


level of complexity

Moderate

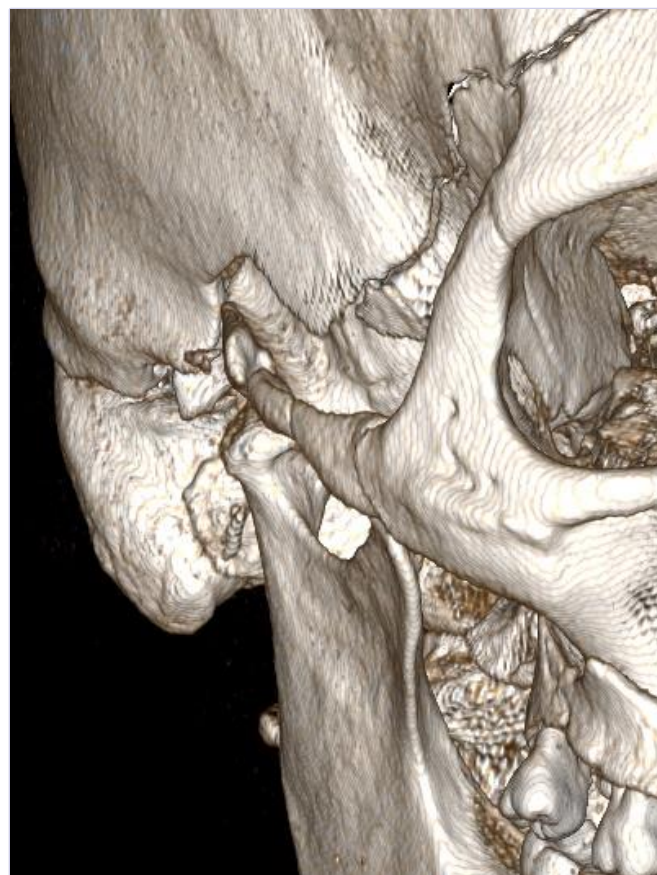
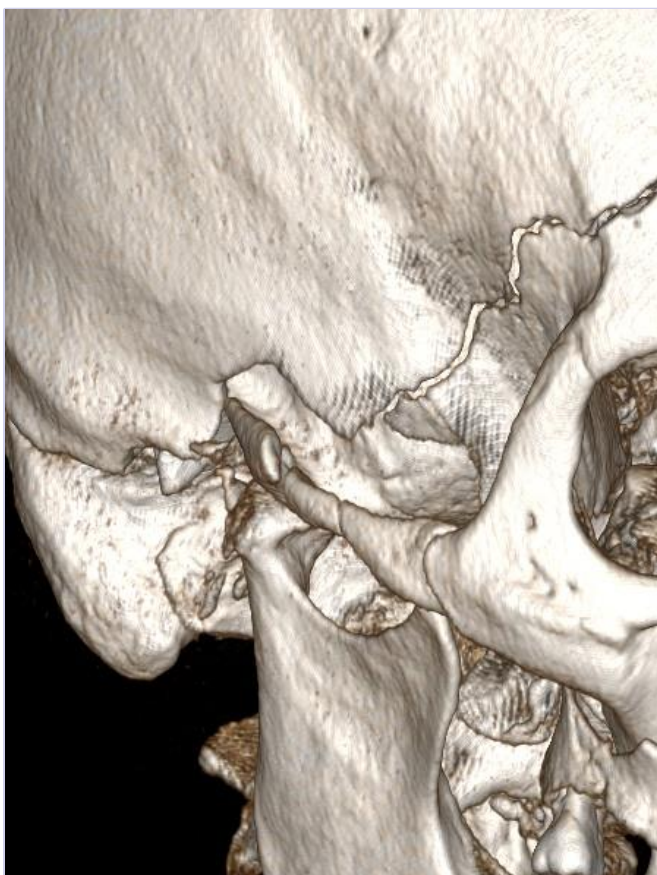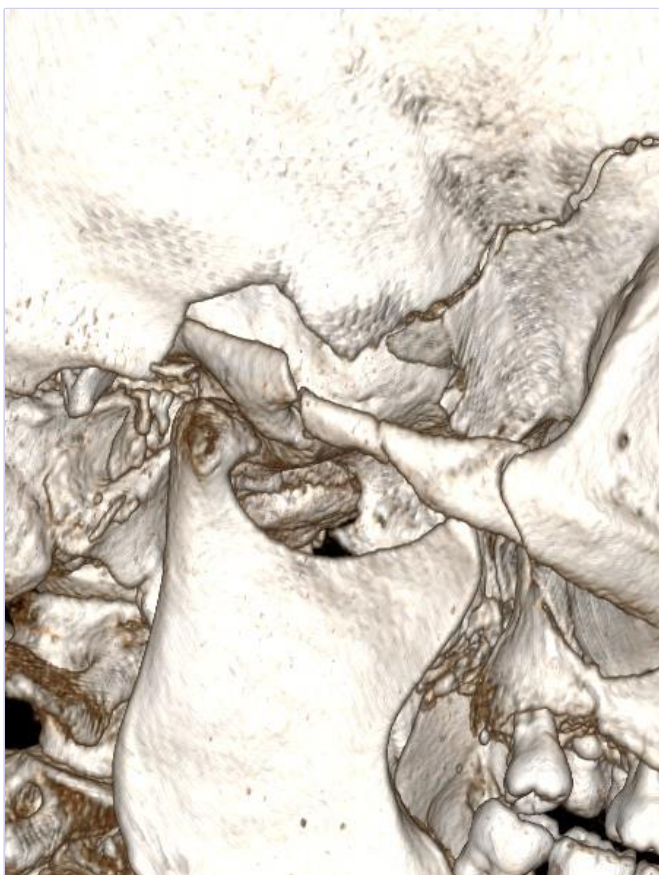
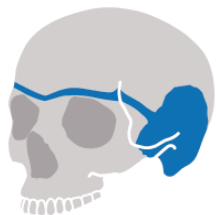Advanced

Master



No CT scan available yet

- Example: 1603314M



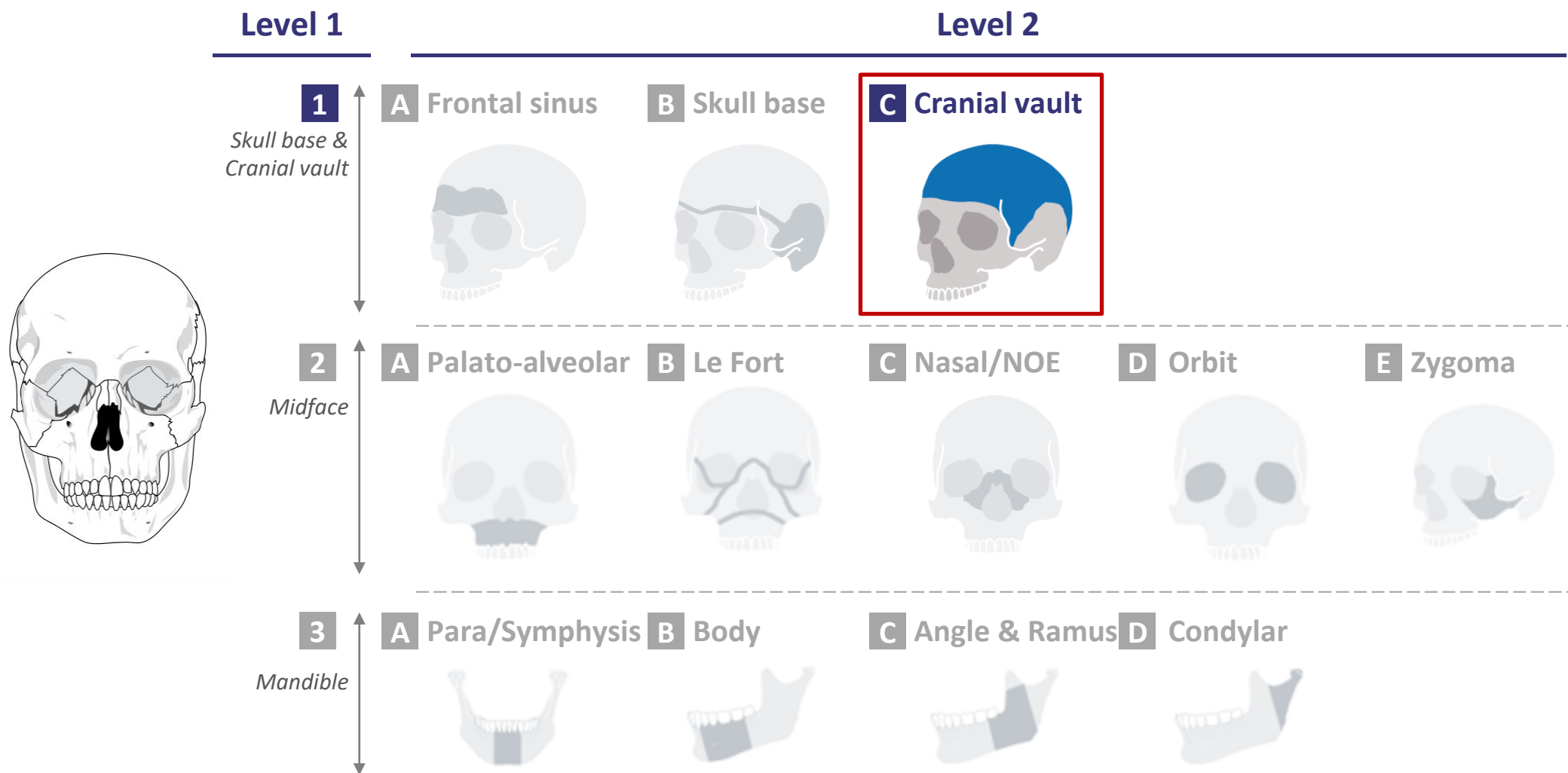
Sex: m

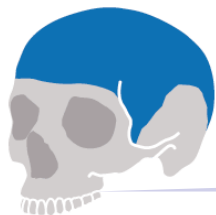Age: 61

BMI: 28

18/07/2018

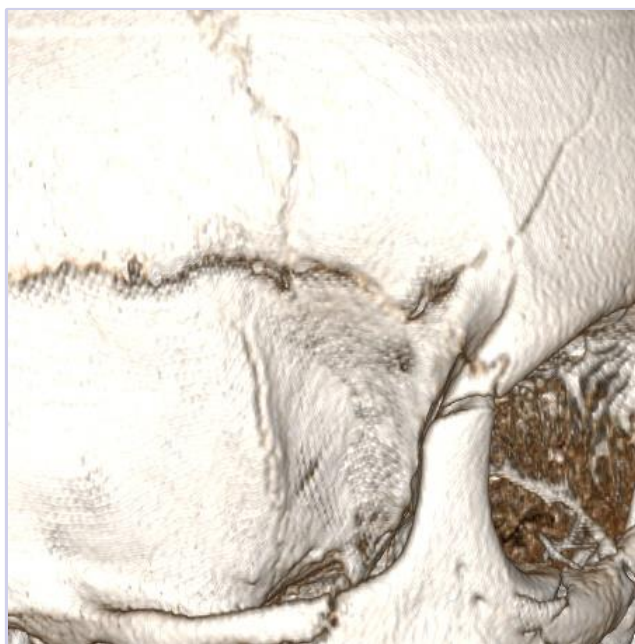
CMF fracture portfolio: 1C-Cranial Vault





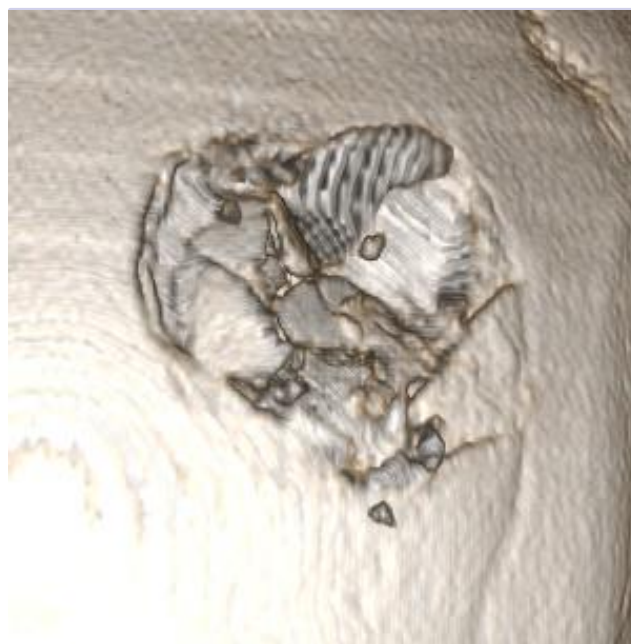
level of complexity

Moderate



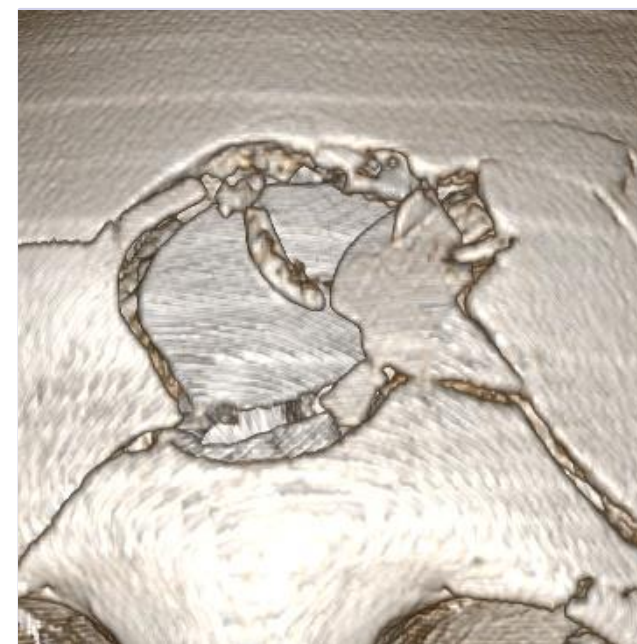
- Example: 1609534R

Advanced

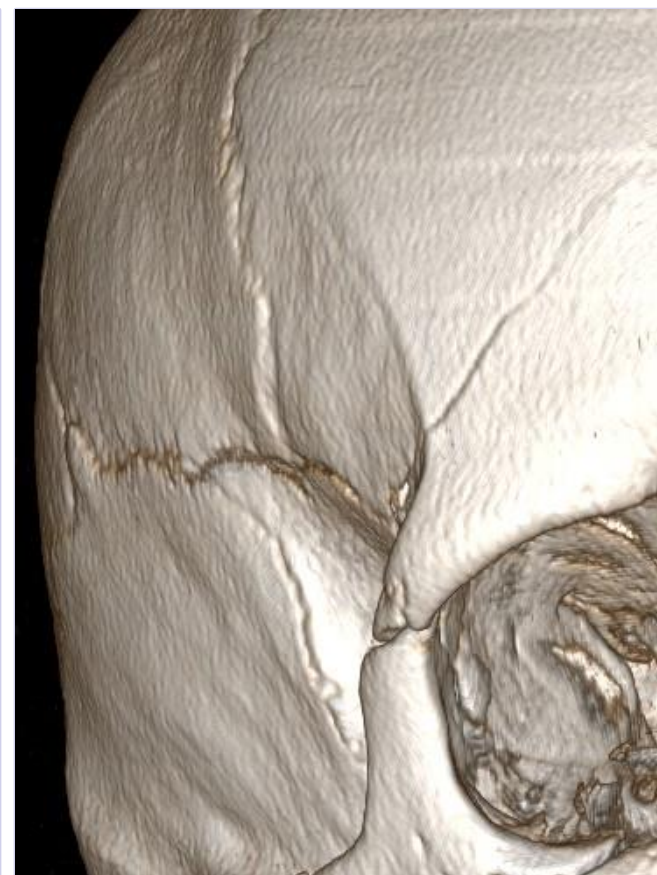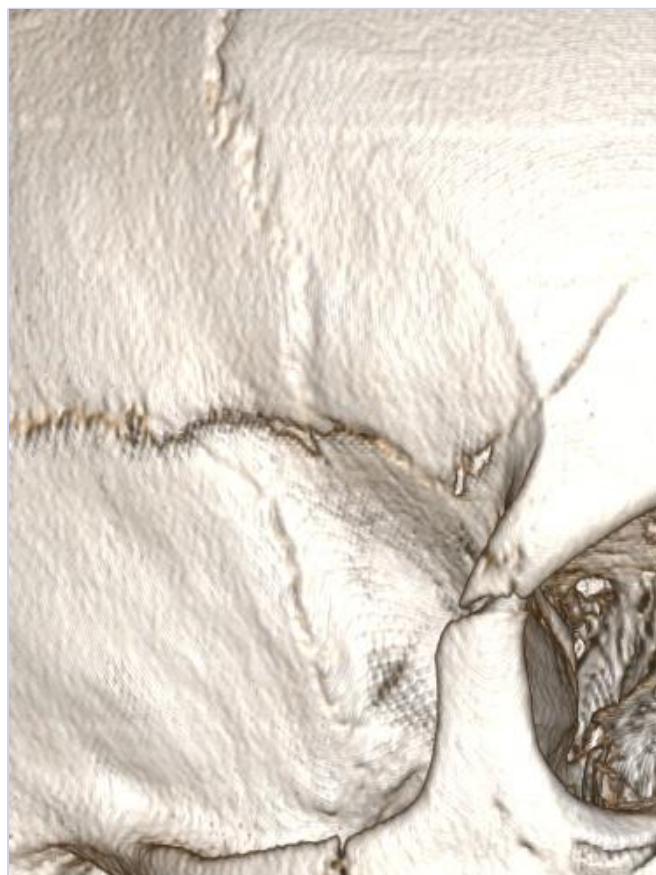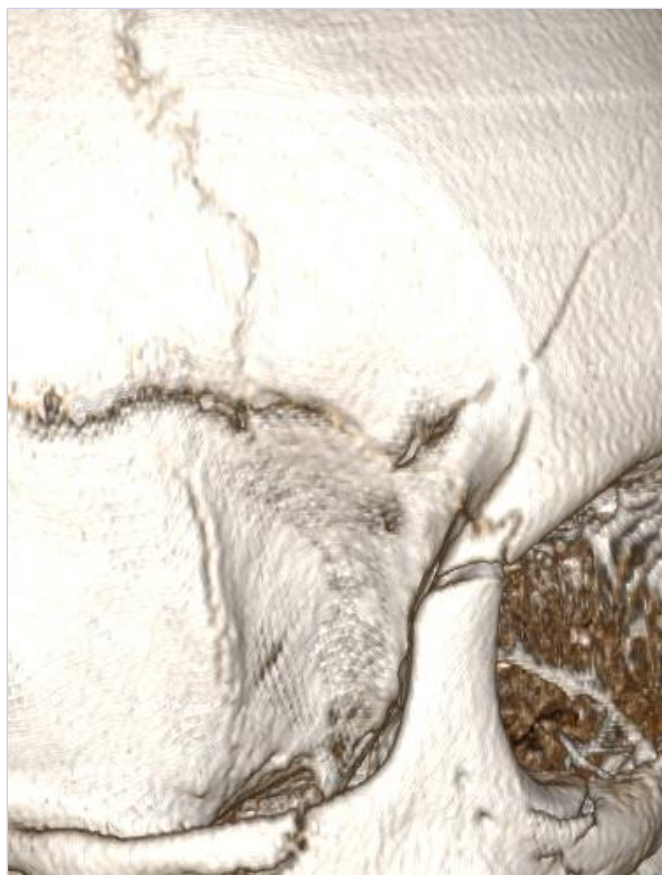


- Example: 1603315M

Master



- Example: 1702045M

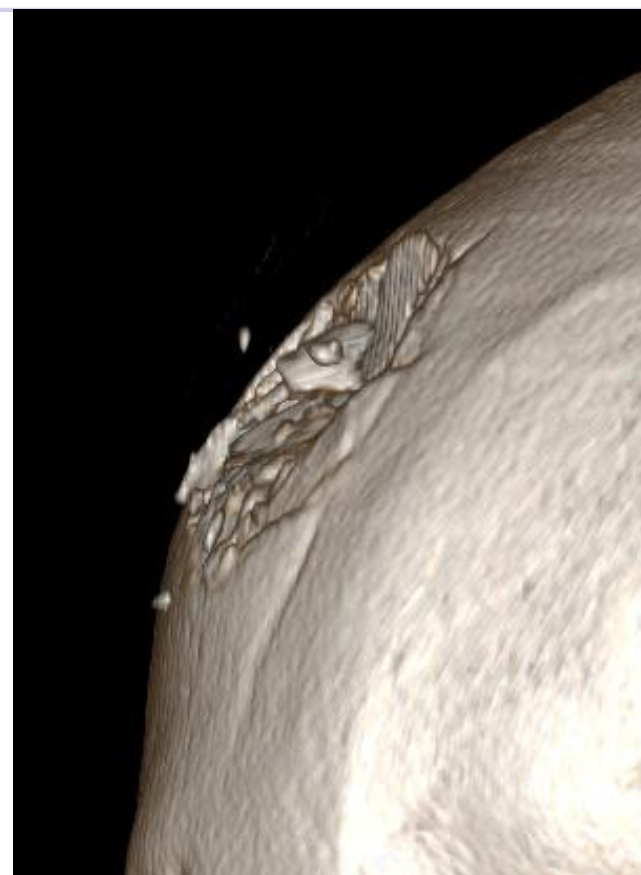
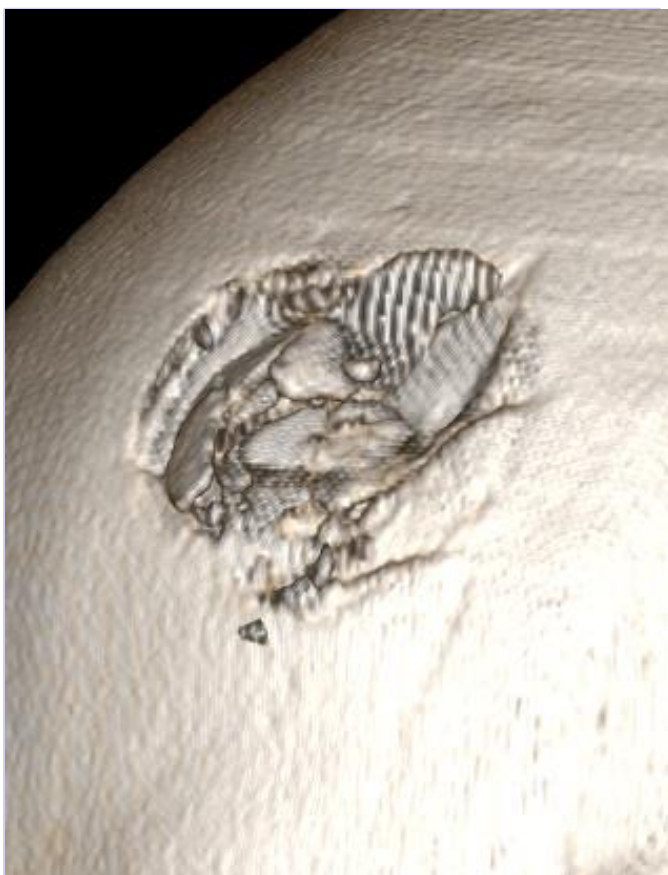
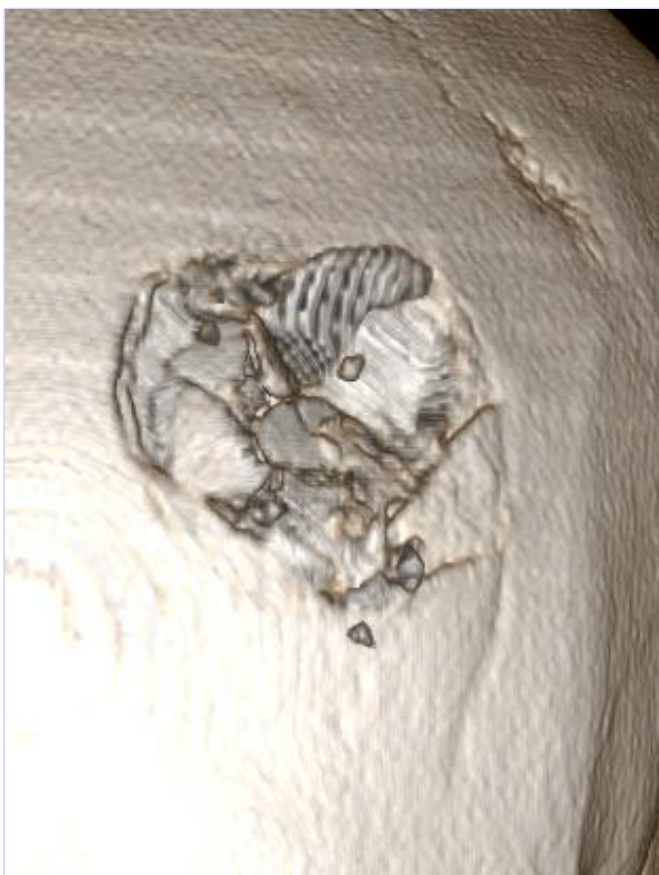

Sex: f

Age: 53

BMI: 32

18/07/2018

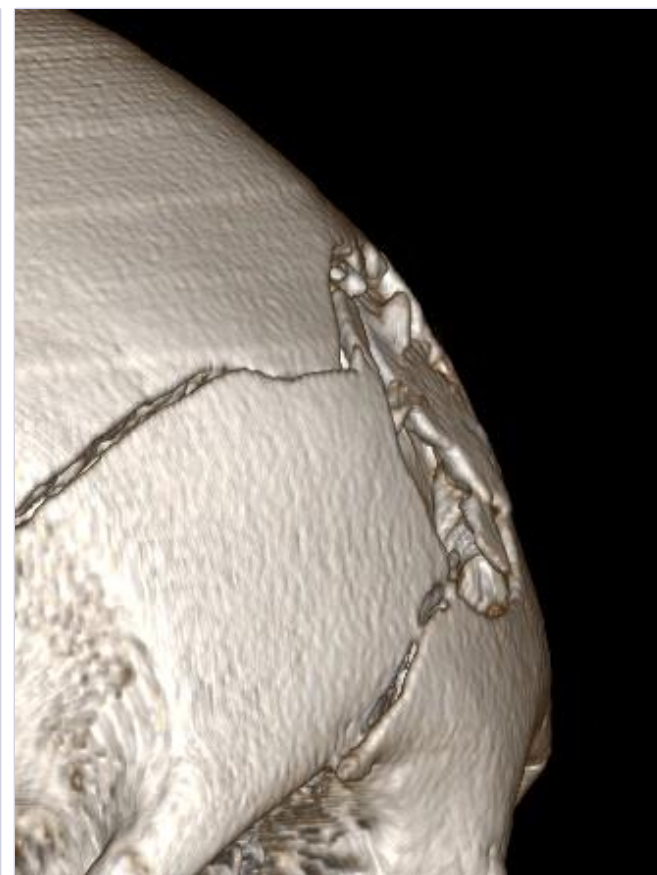
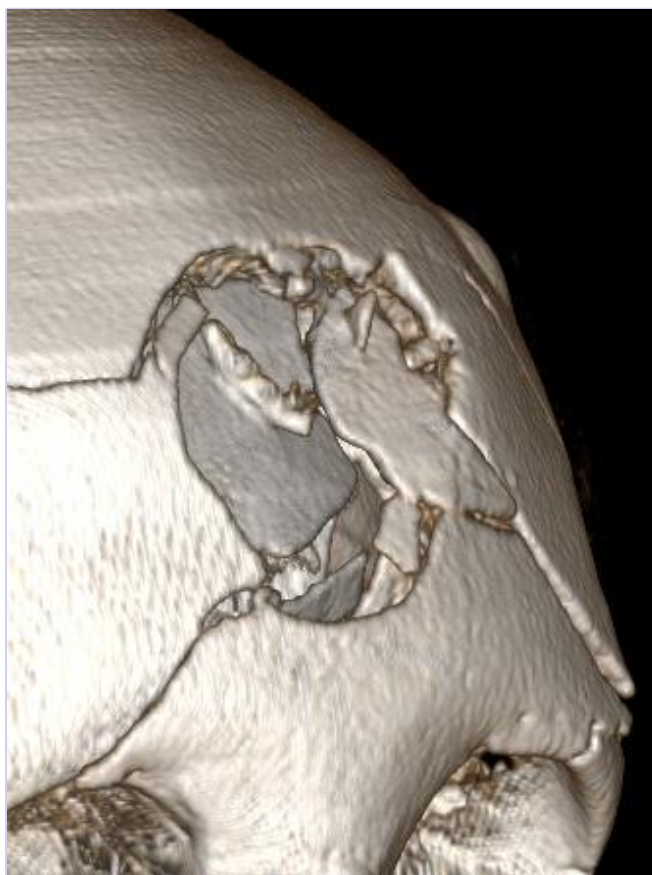
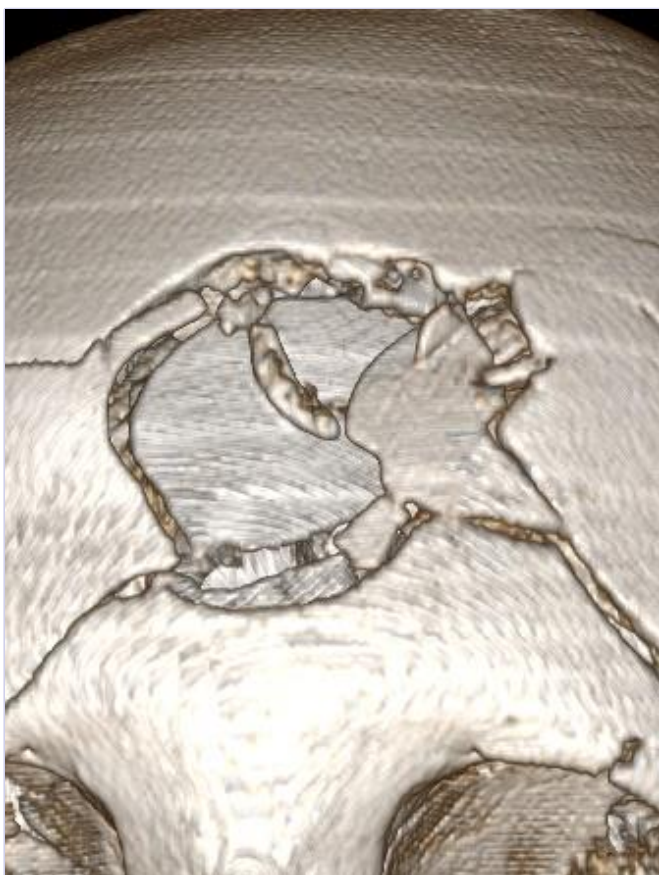
Sex: m

Age: 37

BMI: 40

18/07/2018



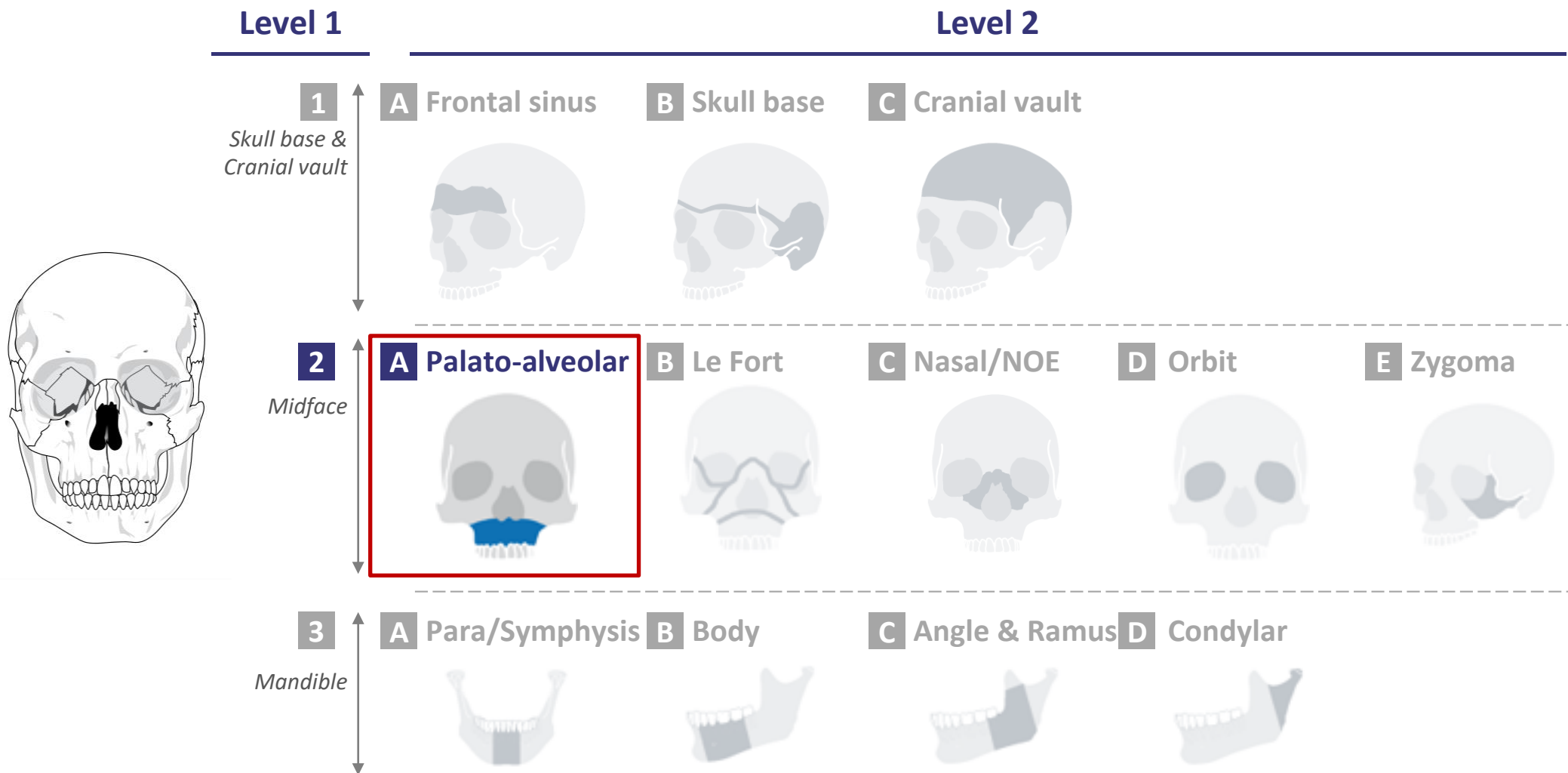
Sex: f

Age: 68

BMI: 25

18/07/2018

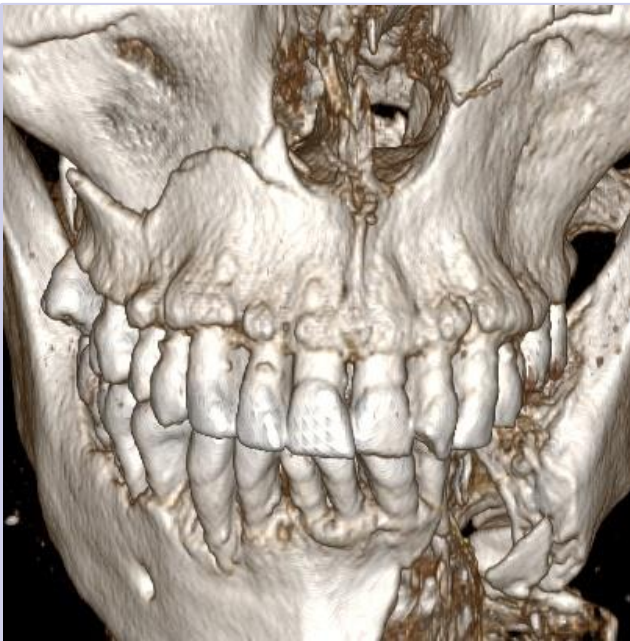CMF fracture portfolio: 2A-Palato-alveolar





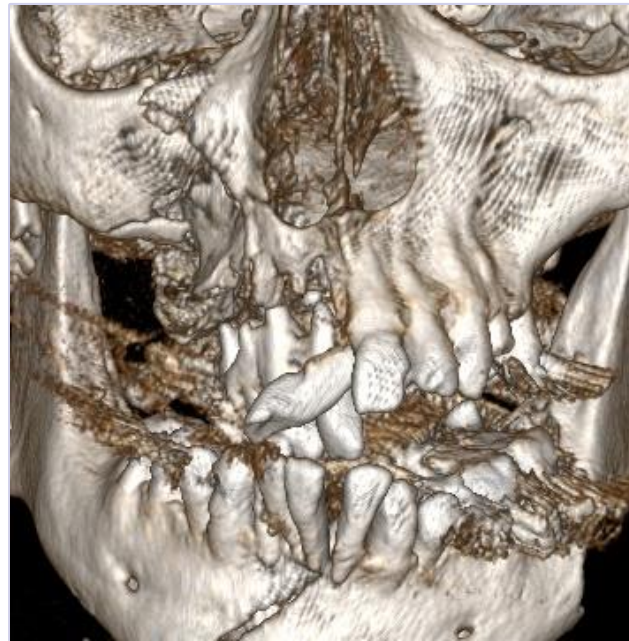level of complexity

Moderate



- Example: 1603314M

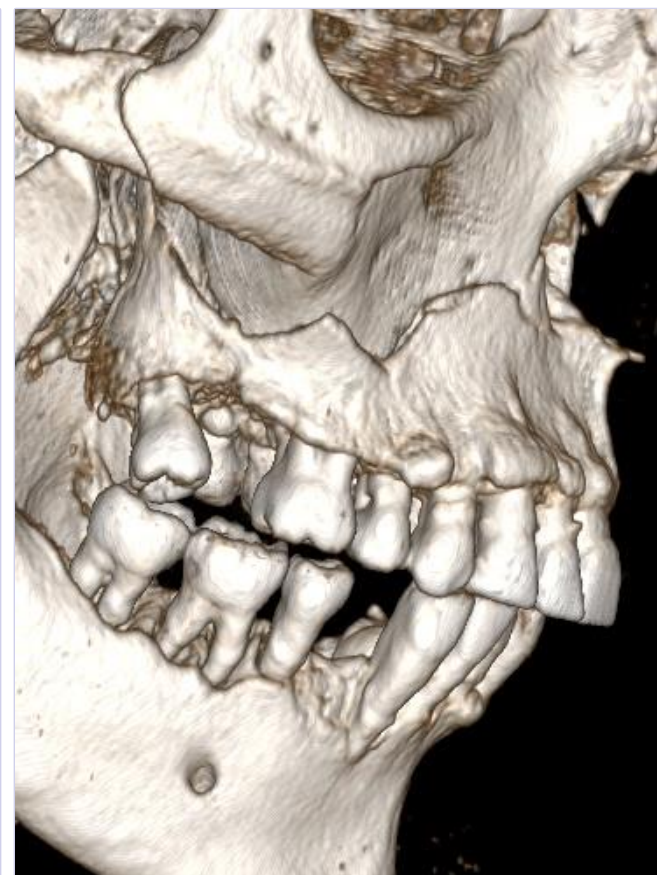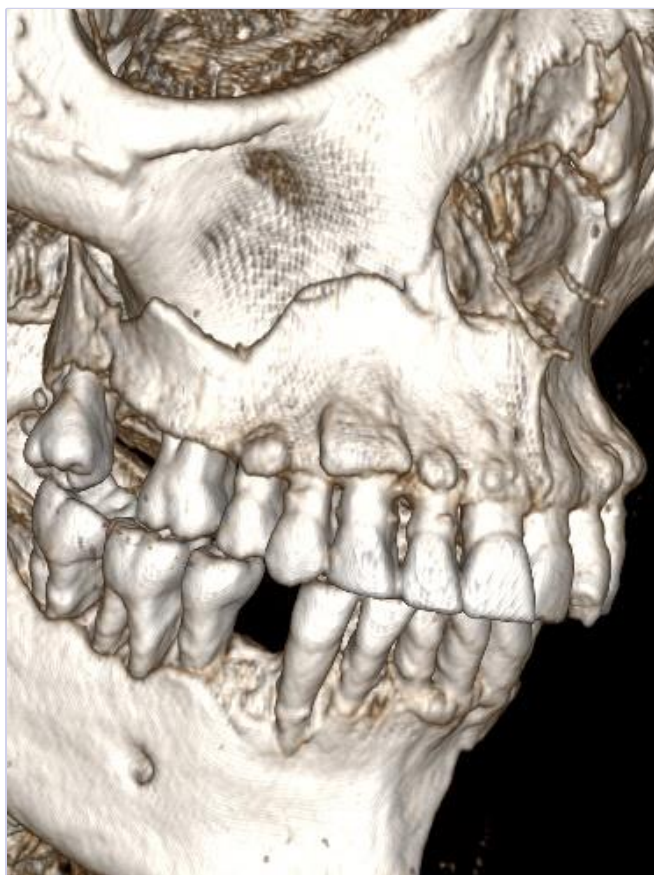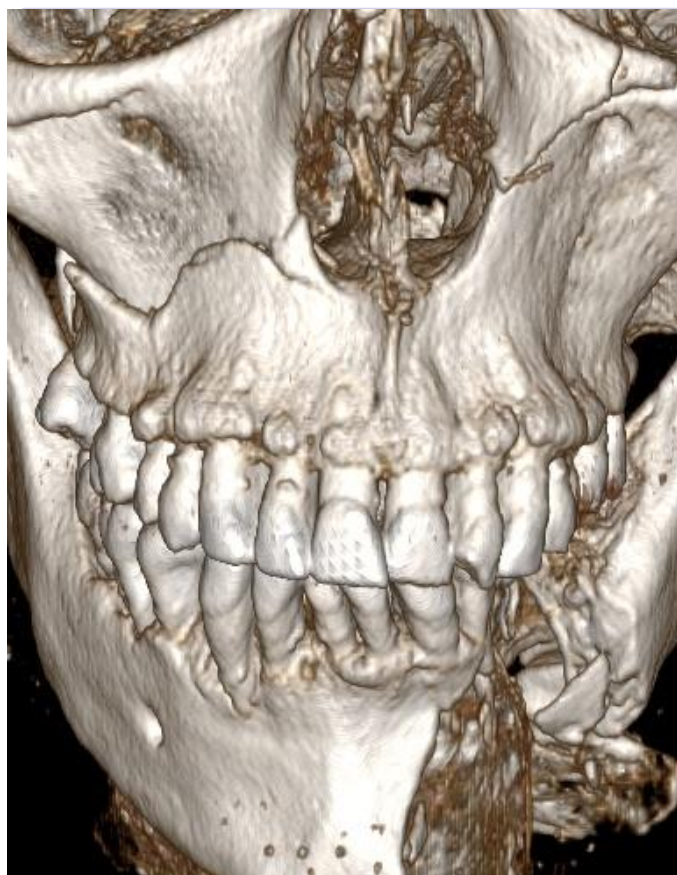Advanced



- Example: F180754

Master

No CT scan available yet

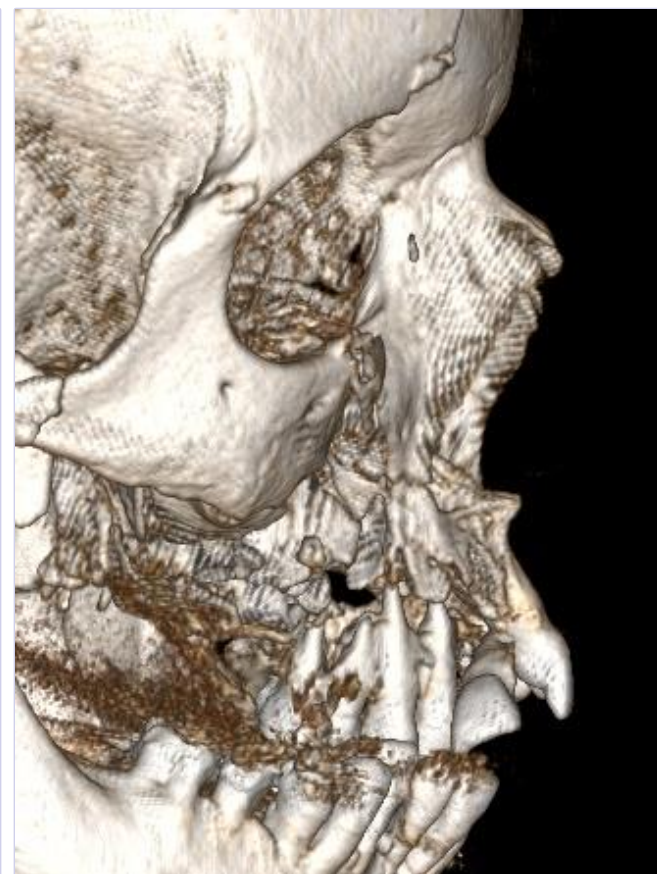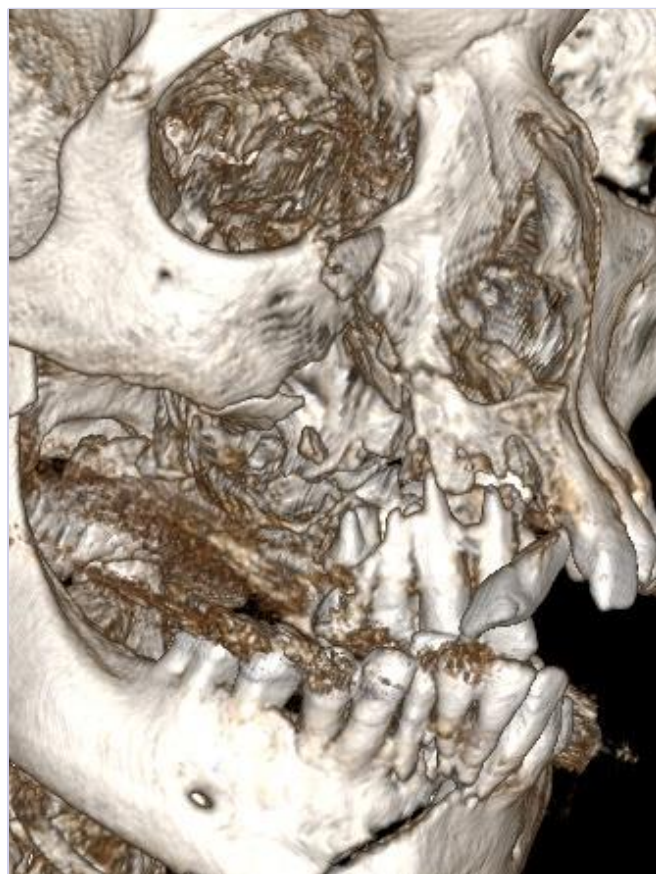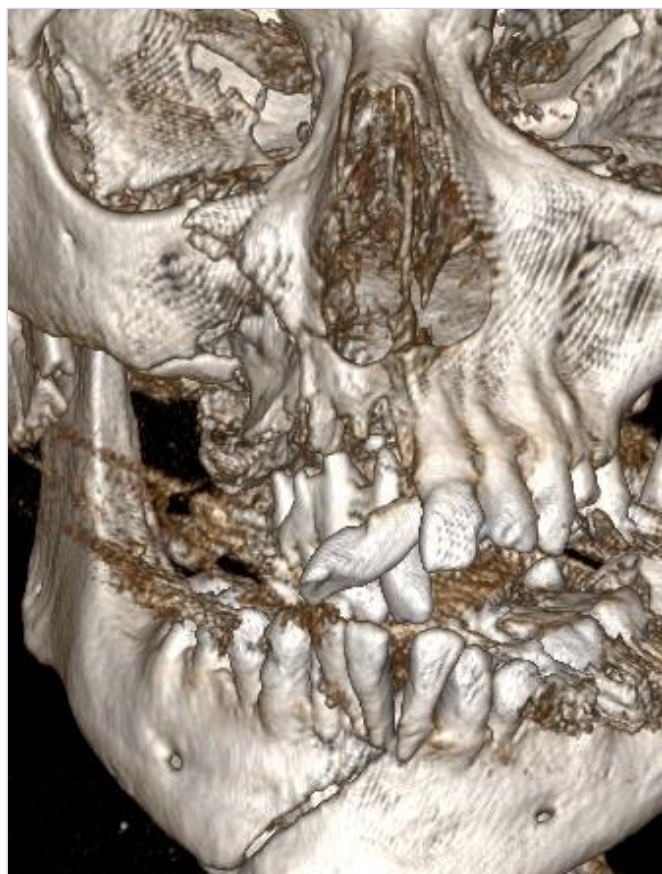


Sex: m

Age: 61

BMI: 28

18/07/2018



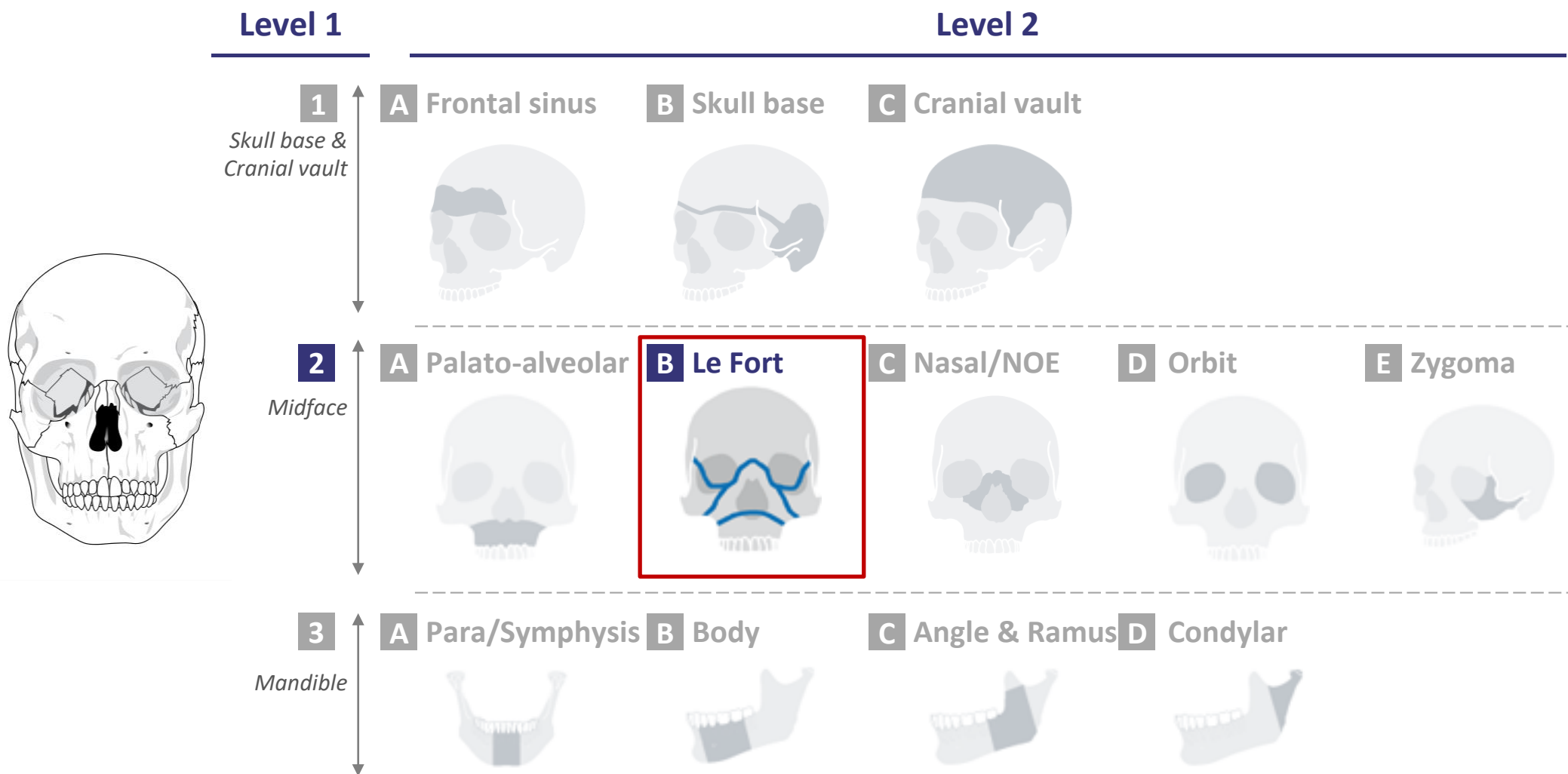
Sex: f

Age: 69

BMI: 21

18/07/2018

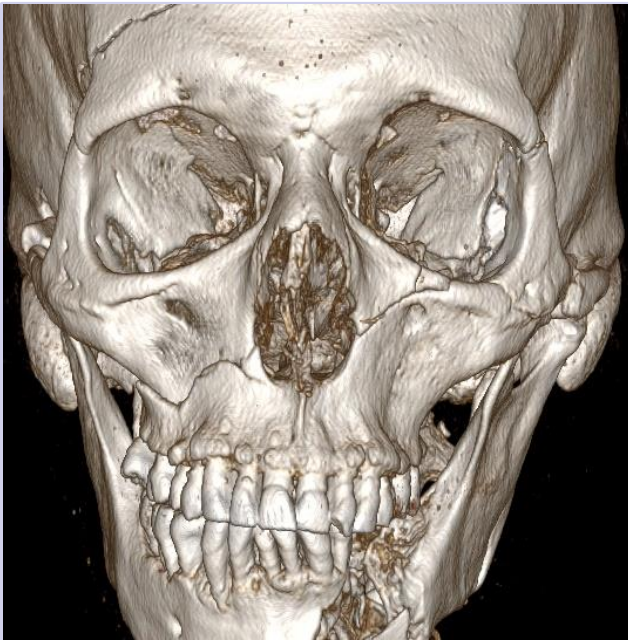
CMF fracture portfolio: 2B-LeFort





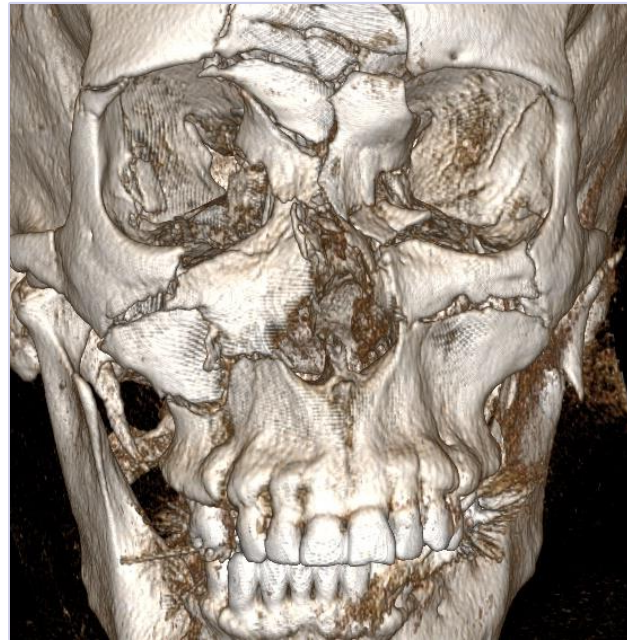level of complexity

Moderate



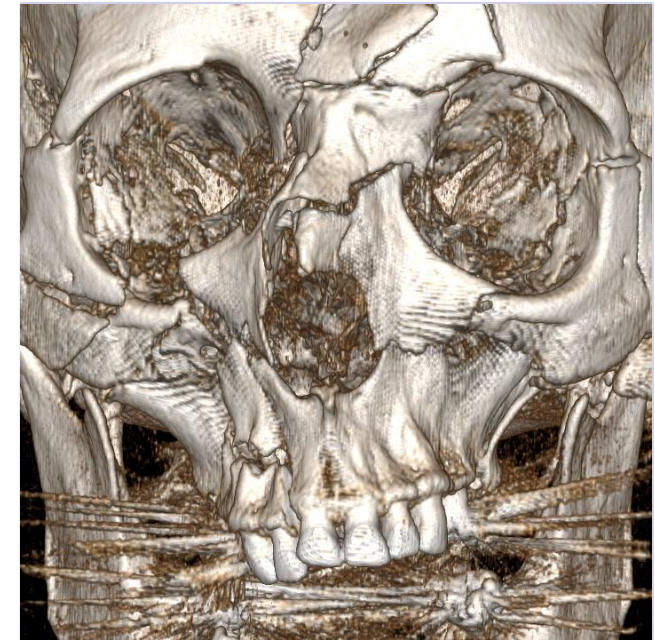
- Example: 1603314M

Advanced

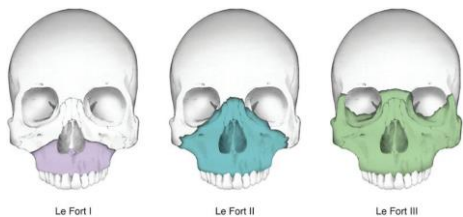


- Example: F180677

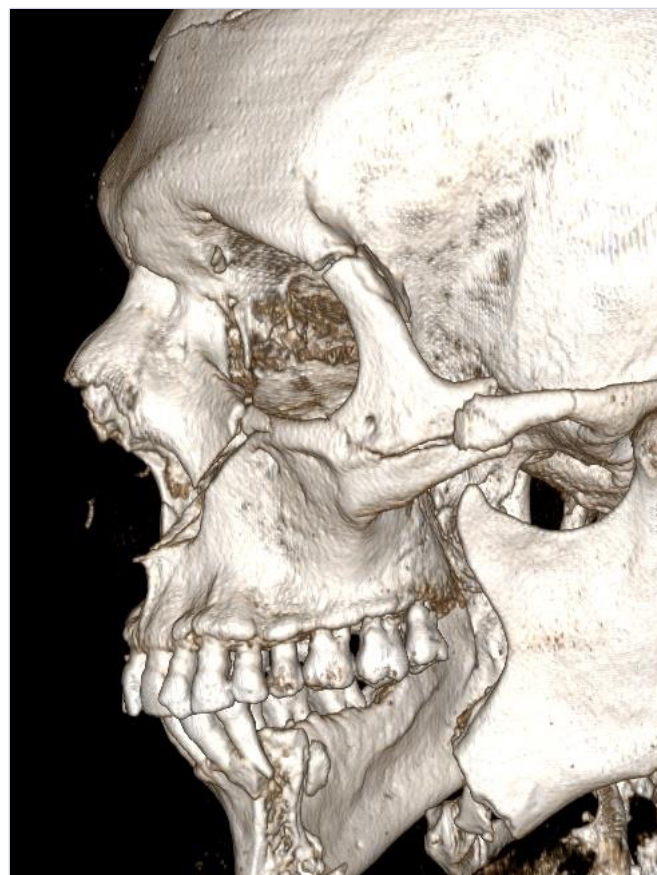
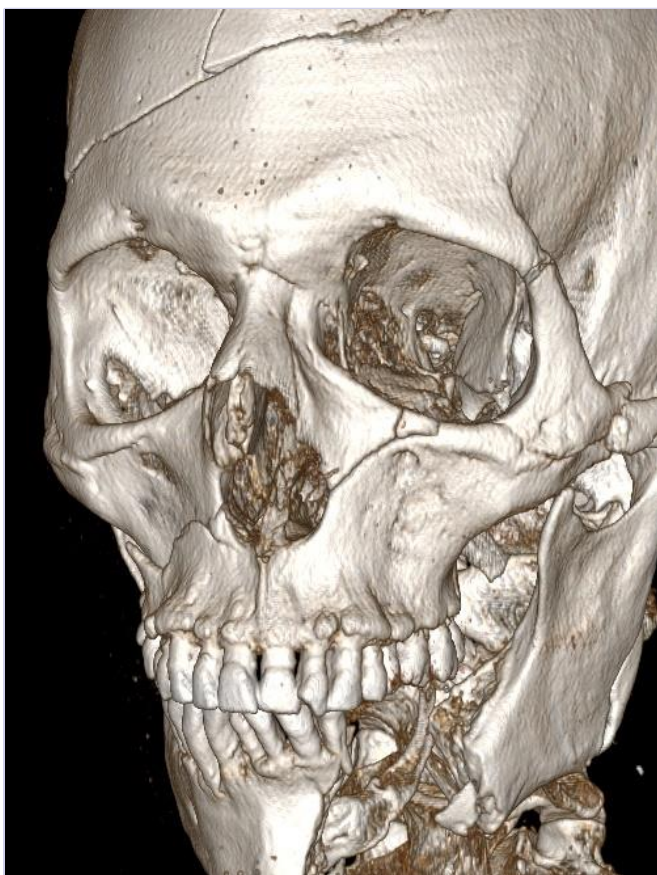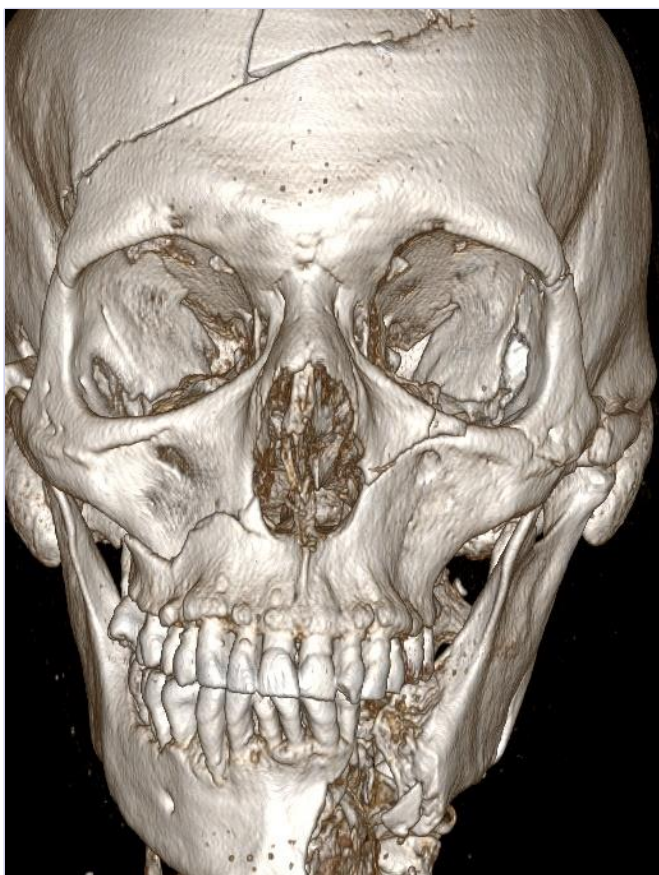Master



- Example: F180655



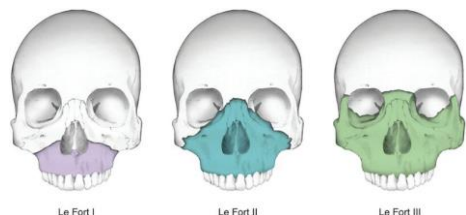
Can be Le Fort I – III or combinations



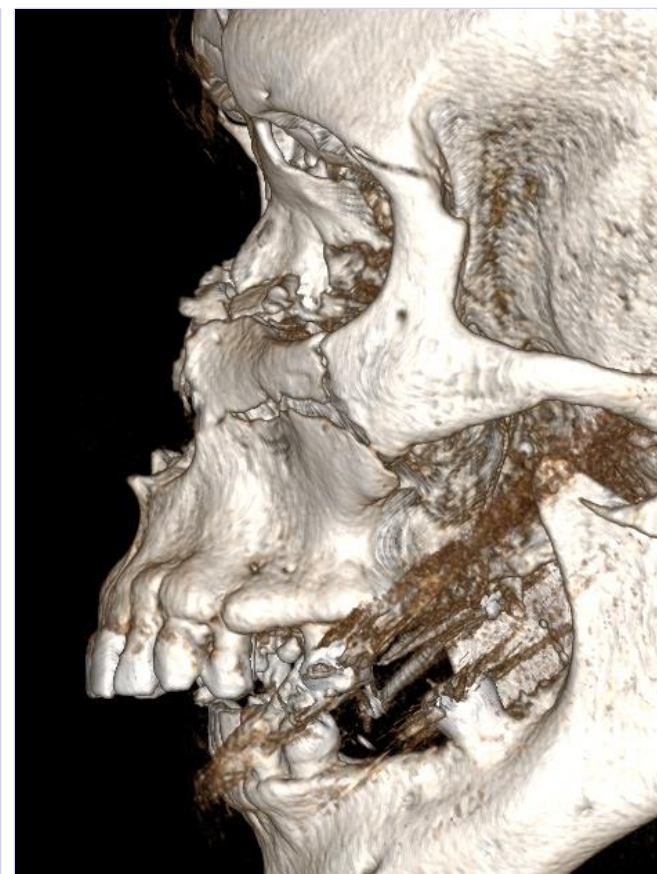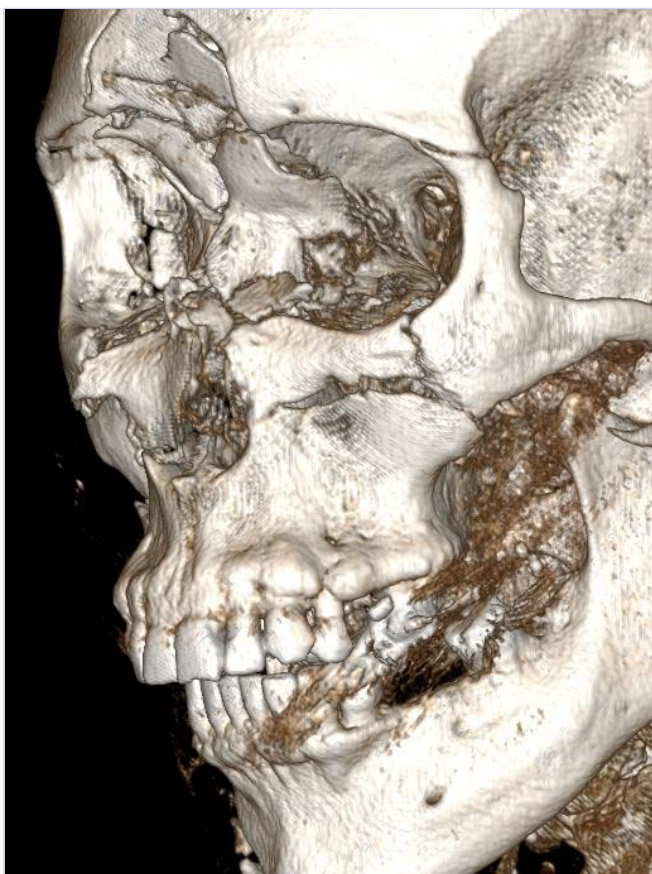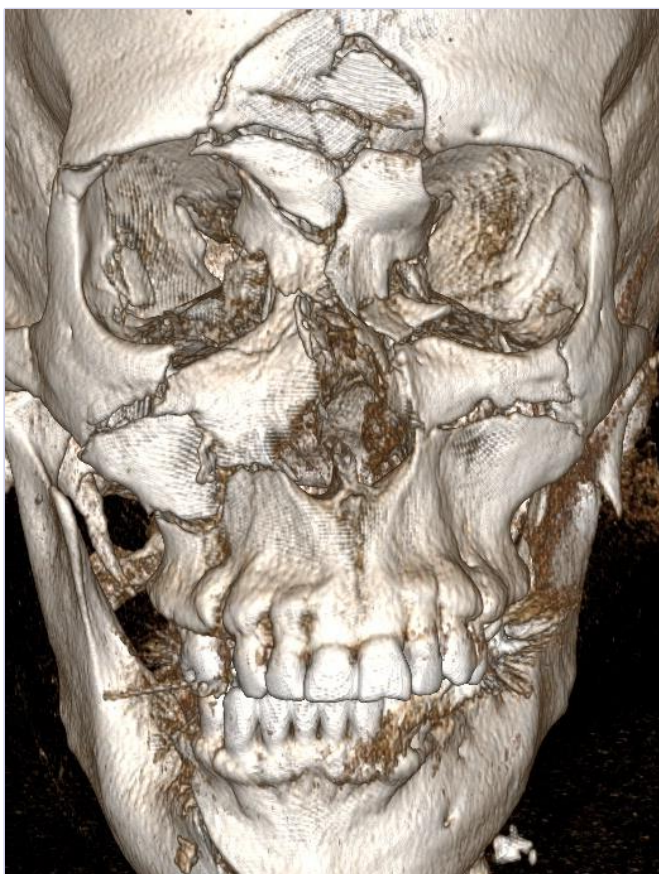
Sex: M

Age: 61

BMI: 28



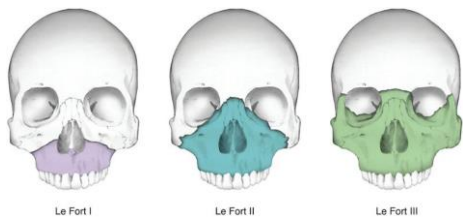
Can be Le Fort I – III or combinations



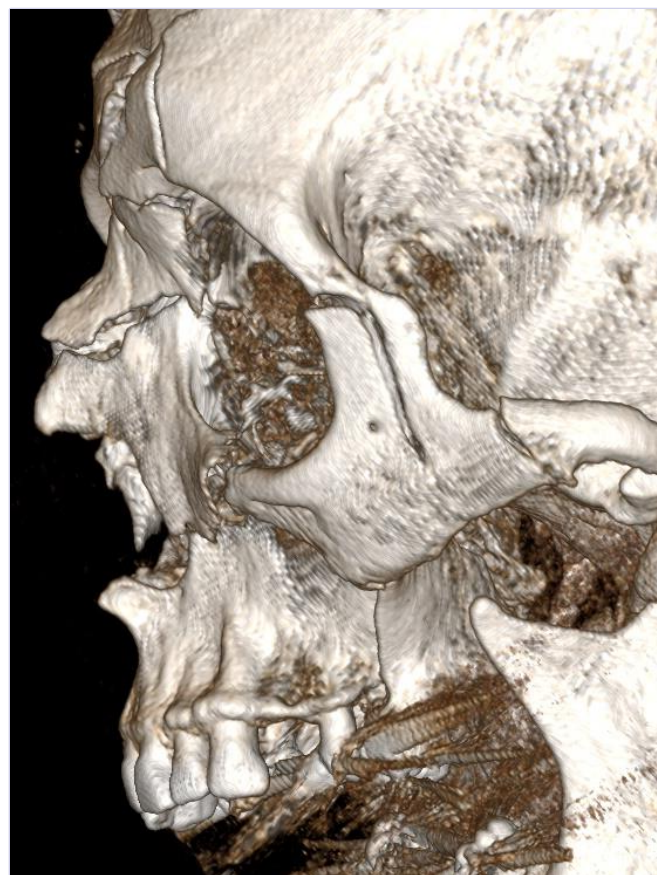
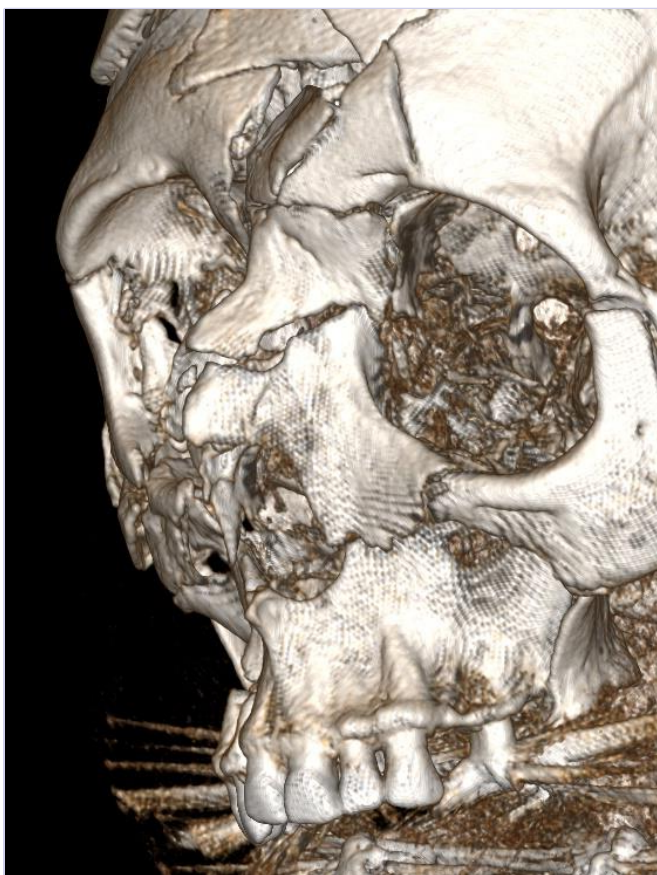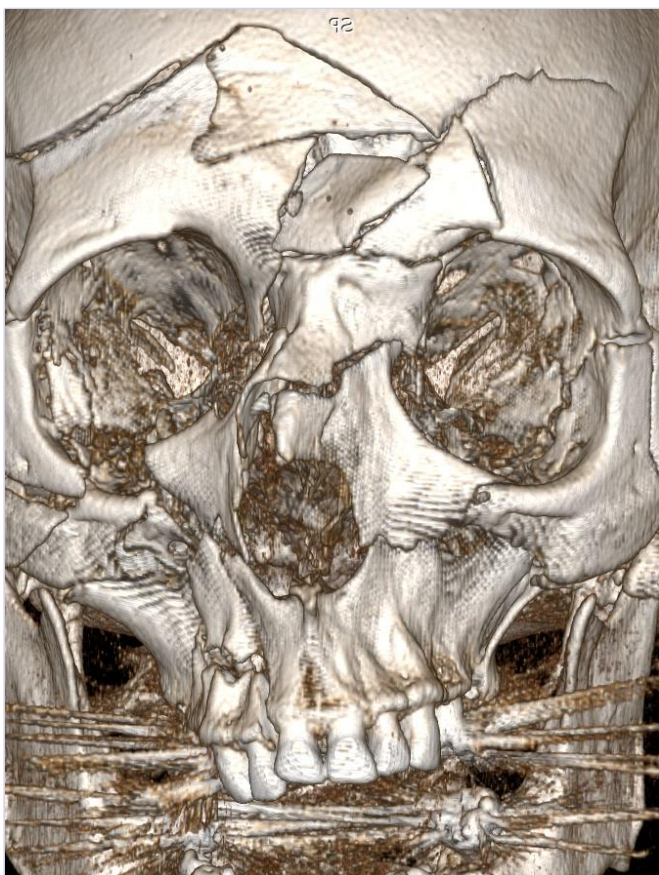
Sex: f

Age: 61

BMI: 24



Can be Le Fort I – III or combinations

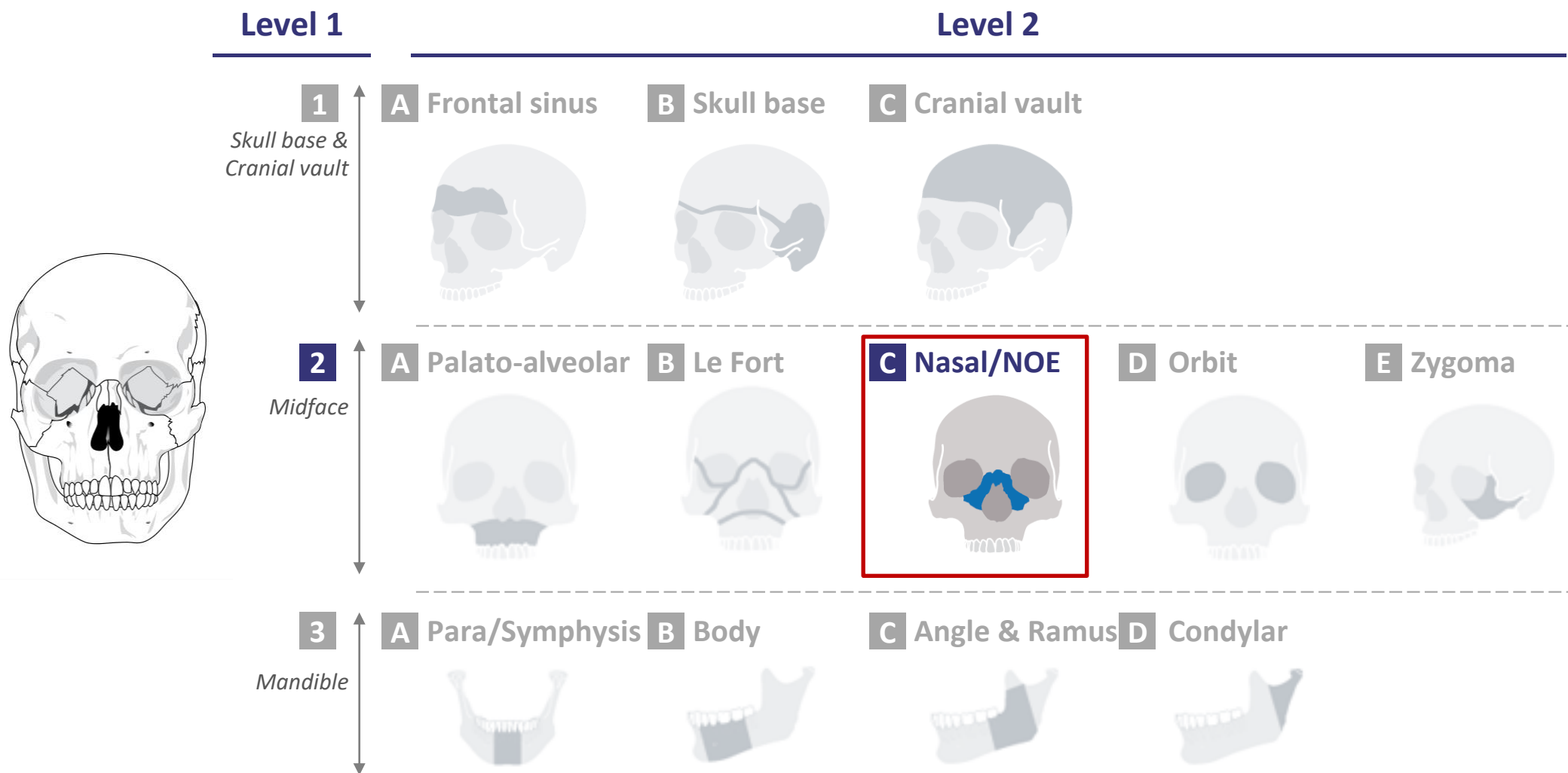


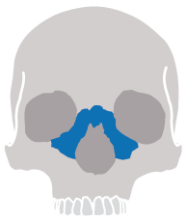Sex: m

Age: 65

BMI: 24

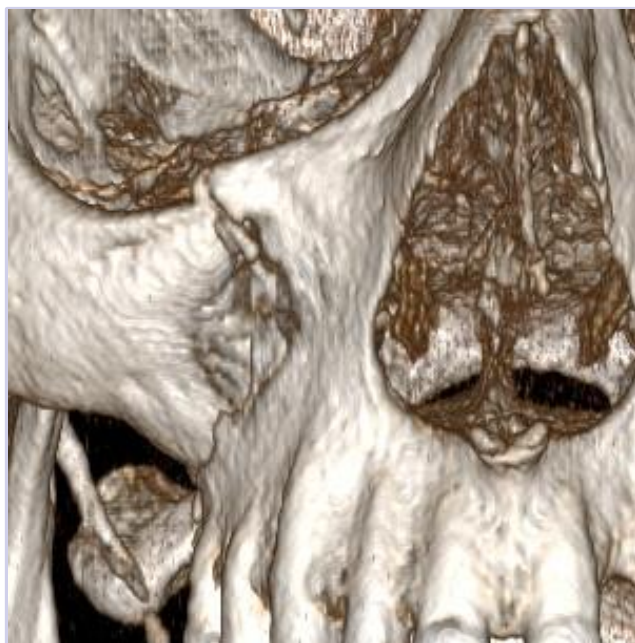
CMF fracture portfolio: 2C-Nasal/NOE





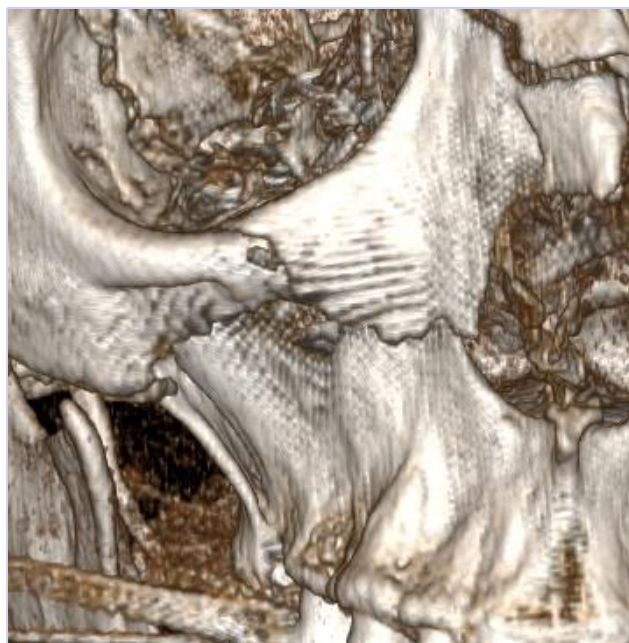
level of complexity

Moderate



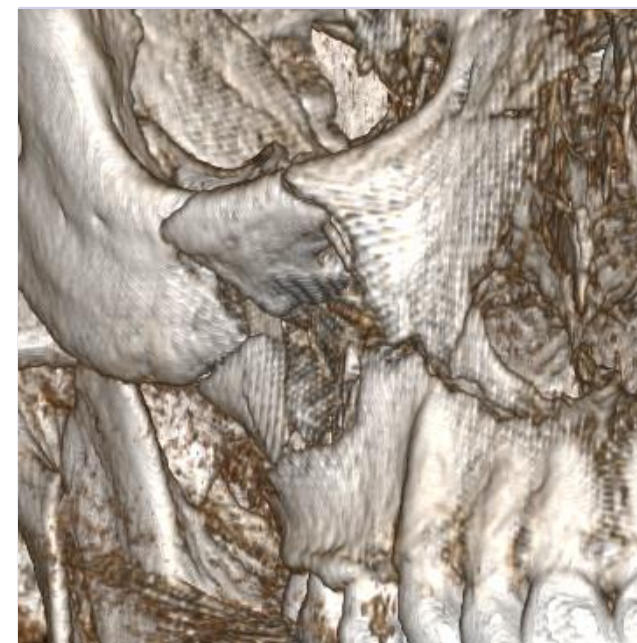
- Example: 1703249M

Advanced

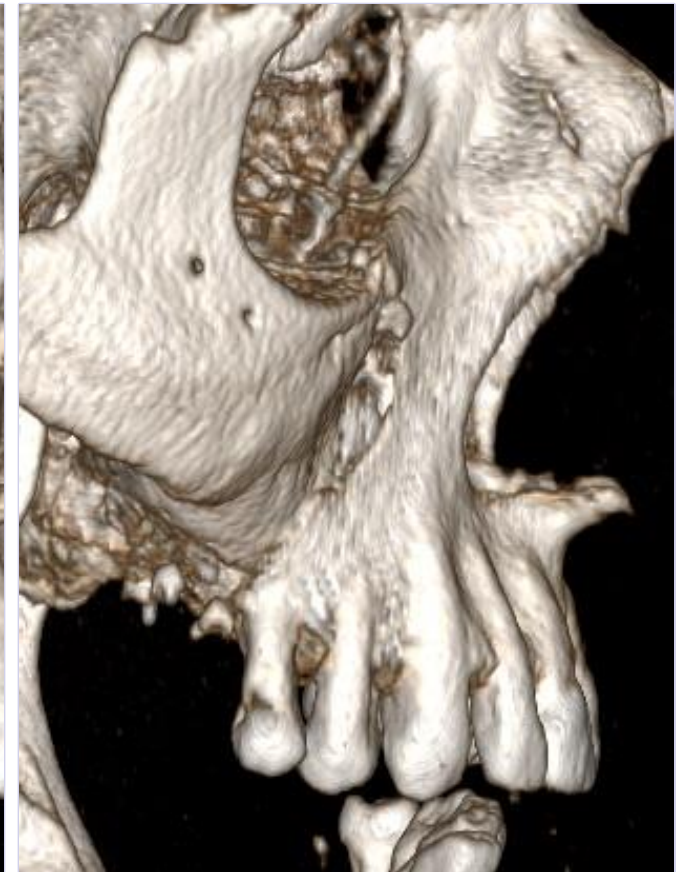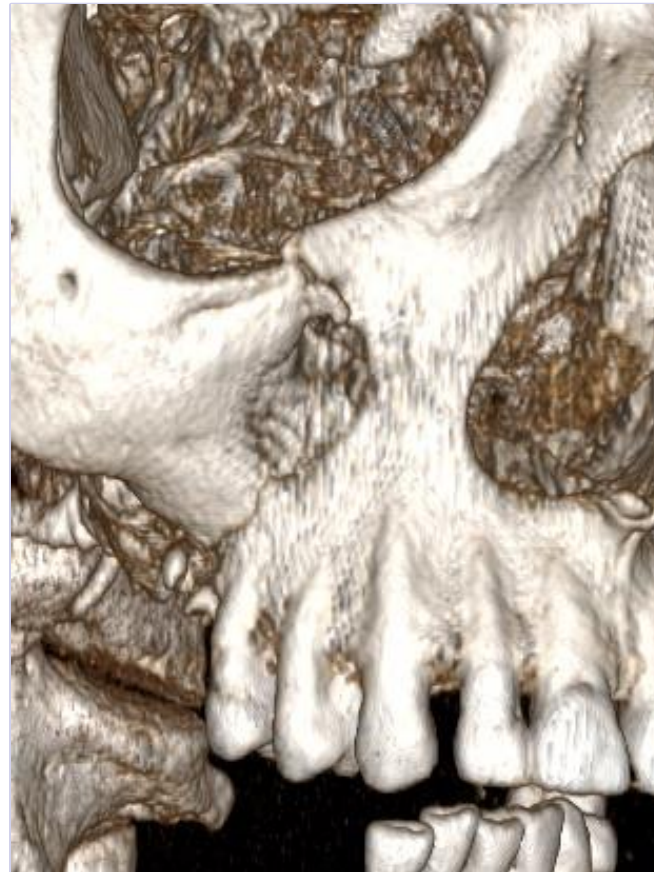
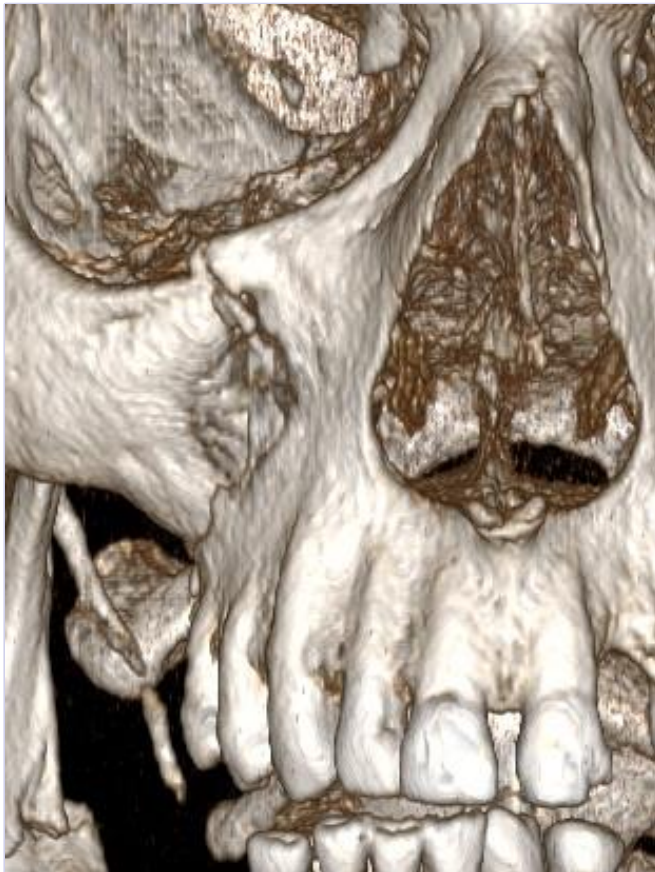

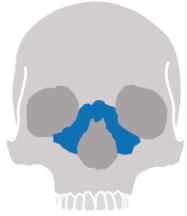
- Example: F180655

Master



- Example: F180616

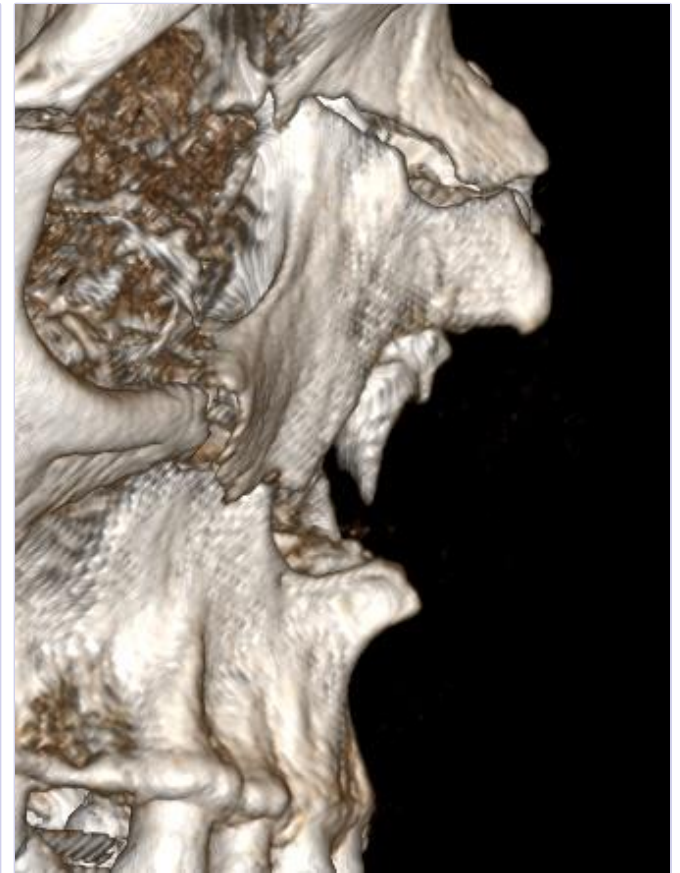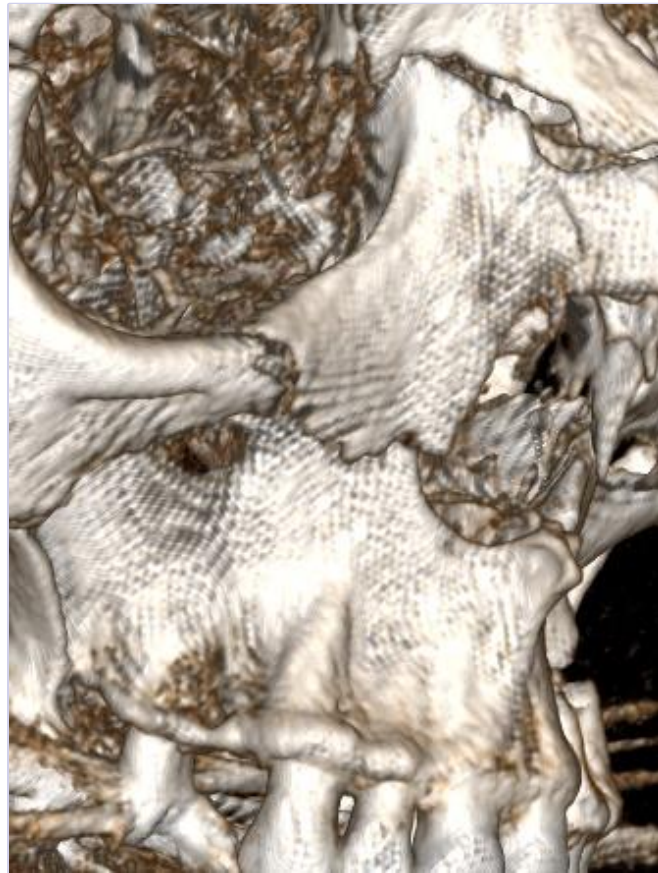

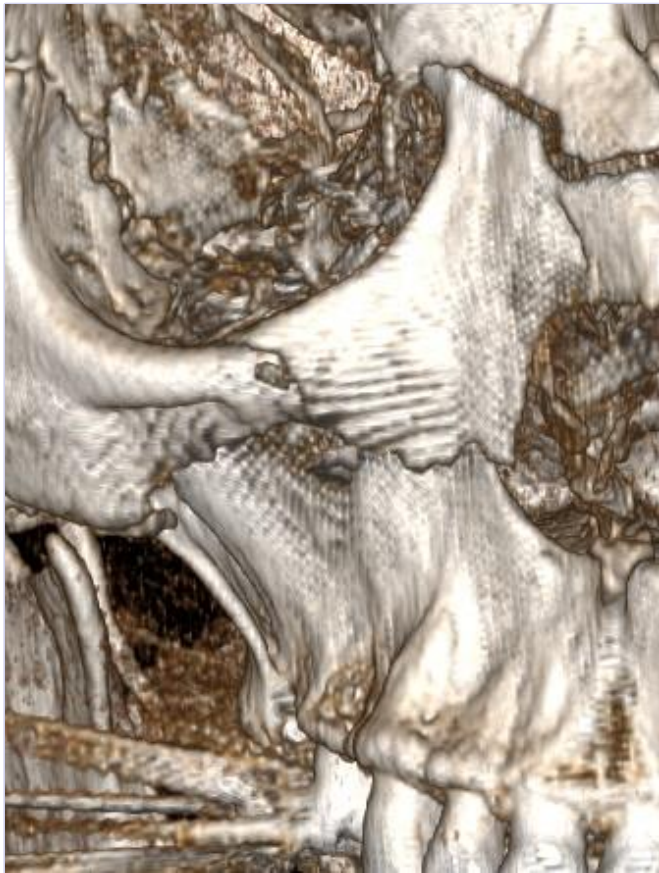
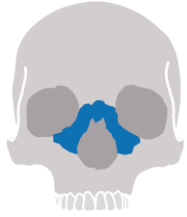Sex: m

Age: 48

BMI: 38

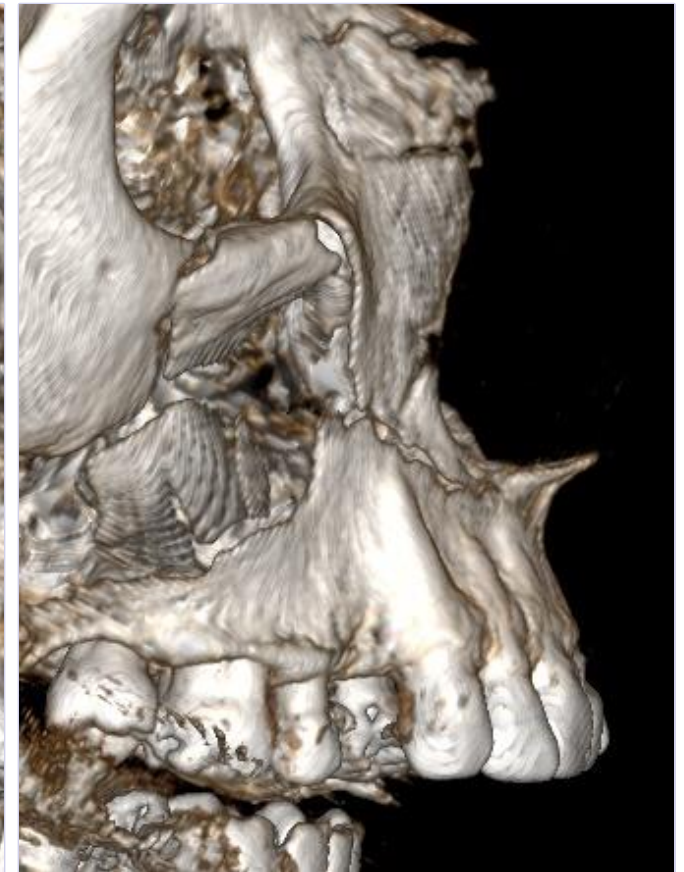
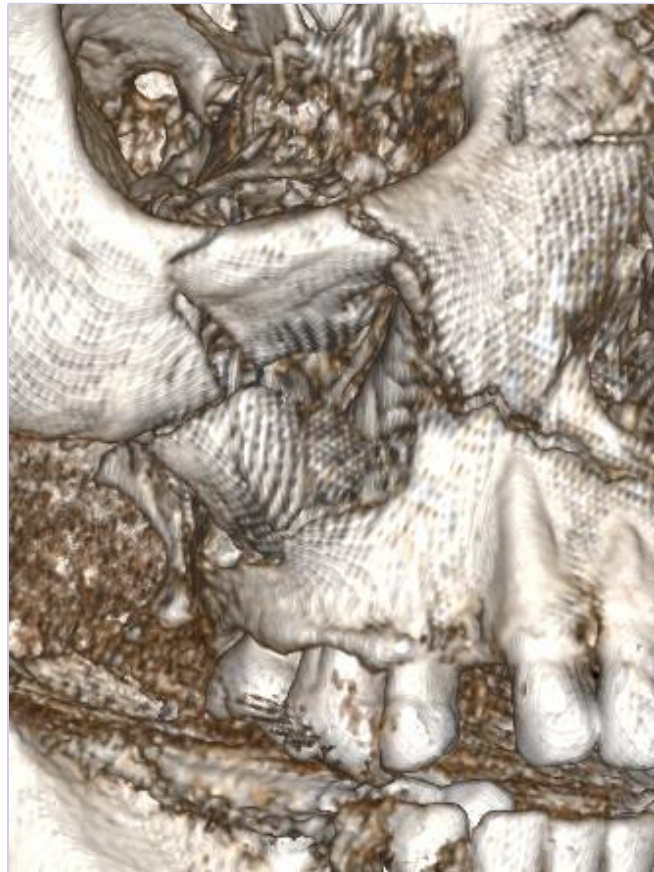
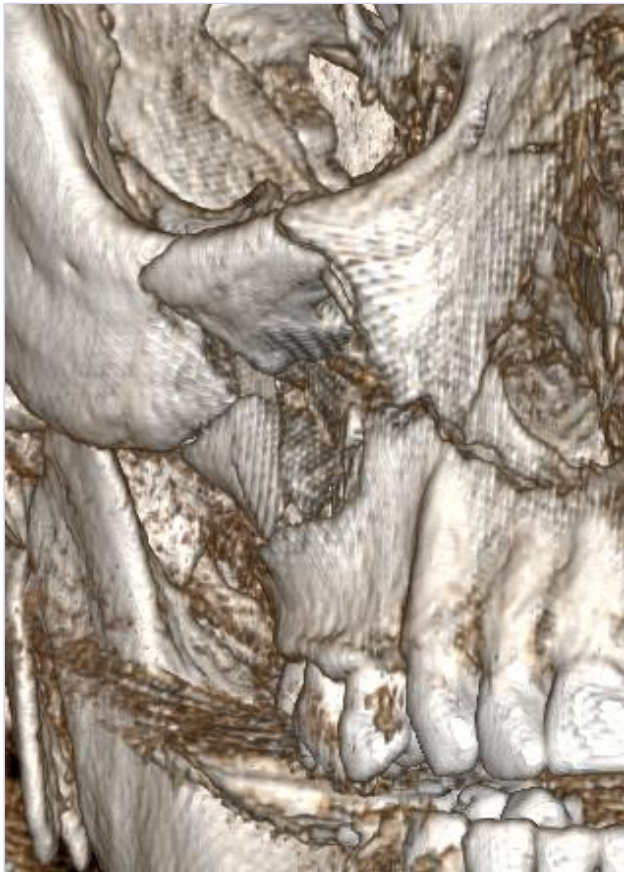18/07/2018



Sex: m

Age: 65

BMI: 24



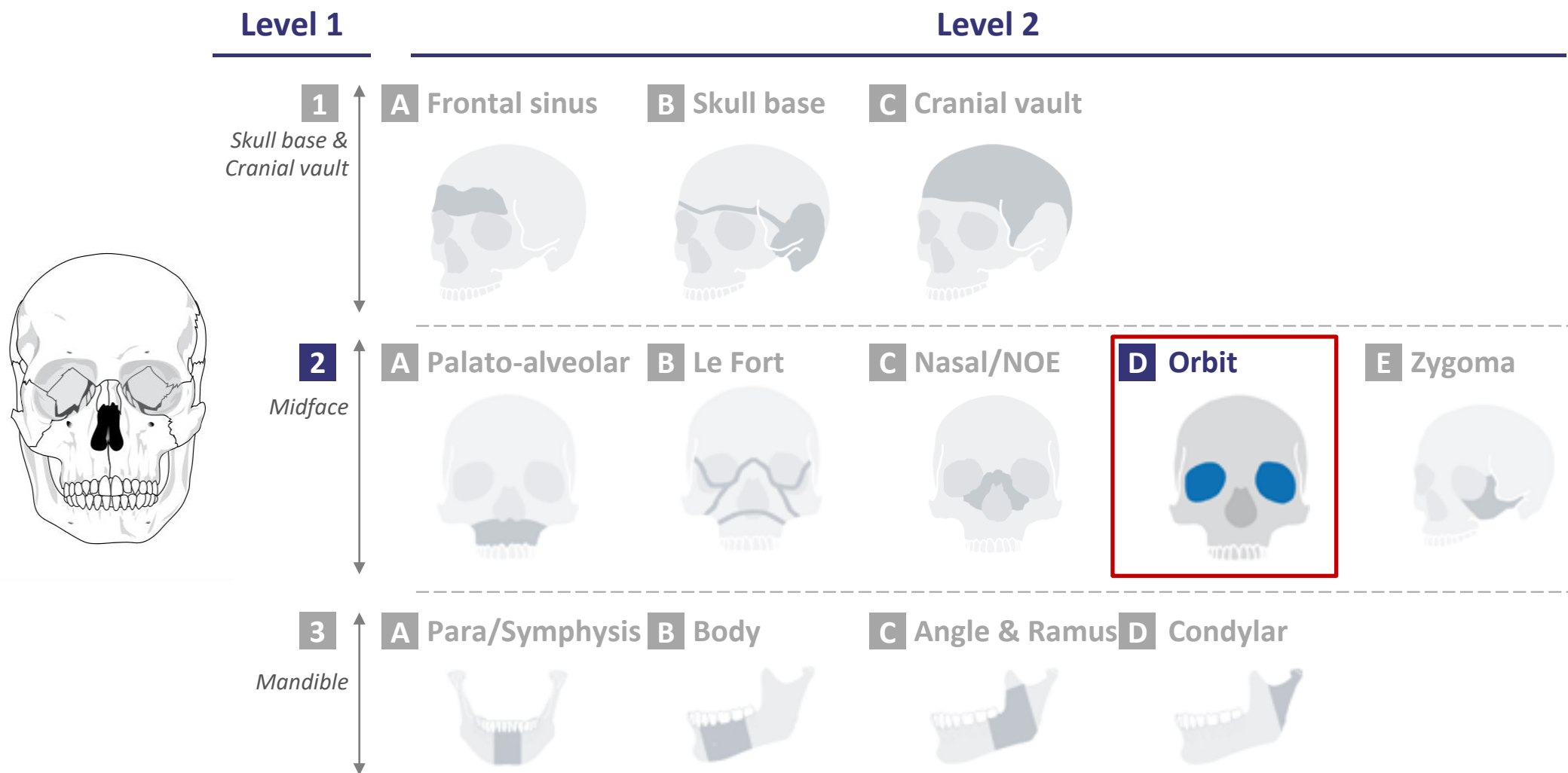
Sex: f

Age: 71

BMI: 20

18/07/2018

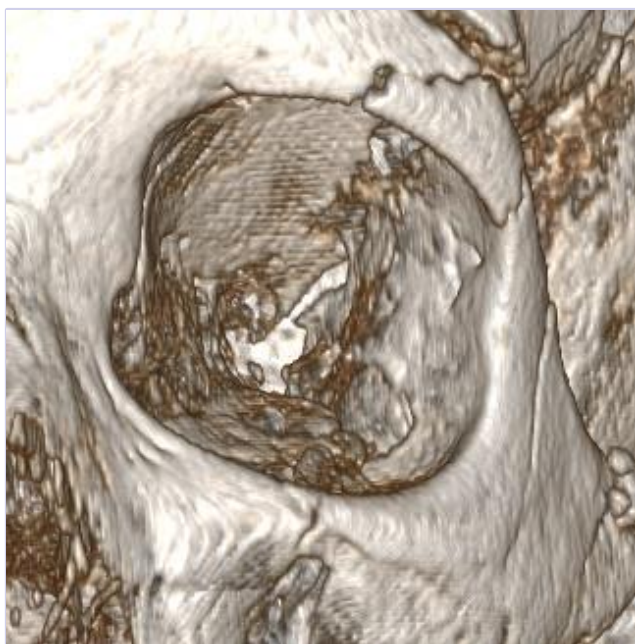
CMF fracture portfolio: 2D-Orbit





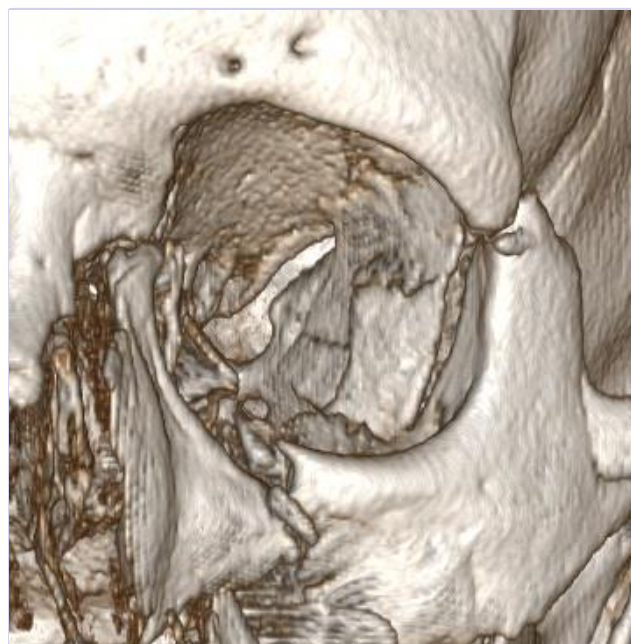
level of complexity

Moderate



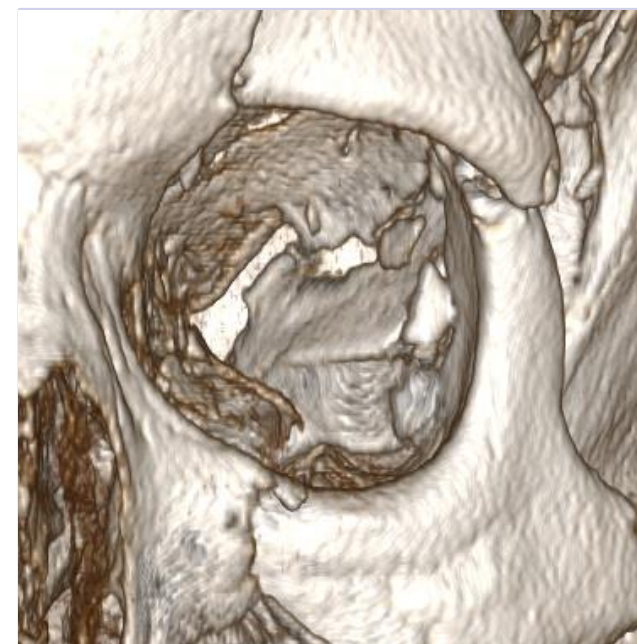
- Example: 1702045M

Advanced

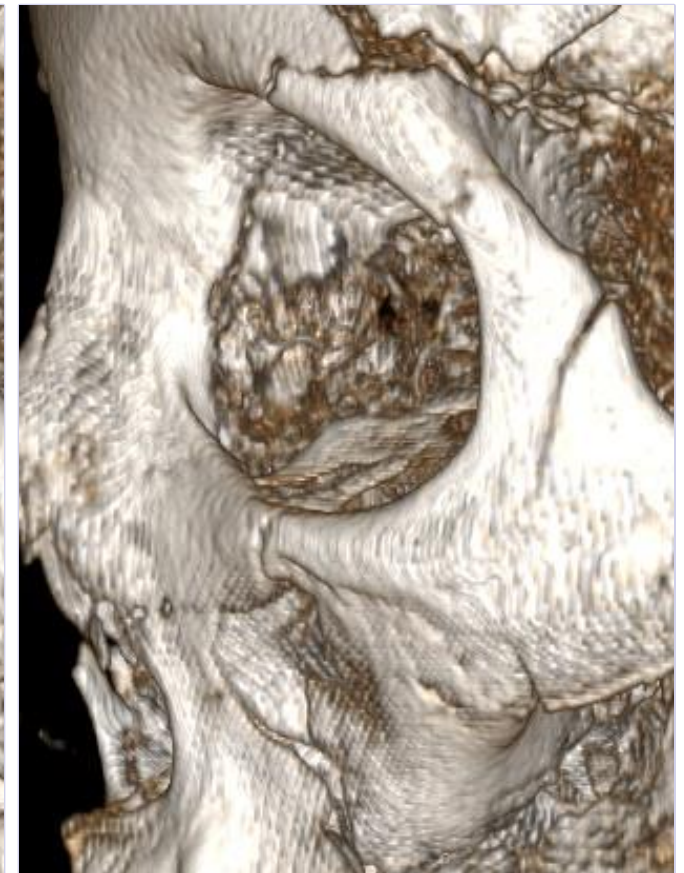
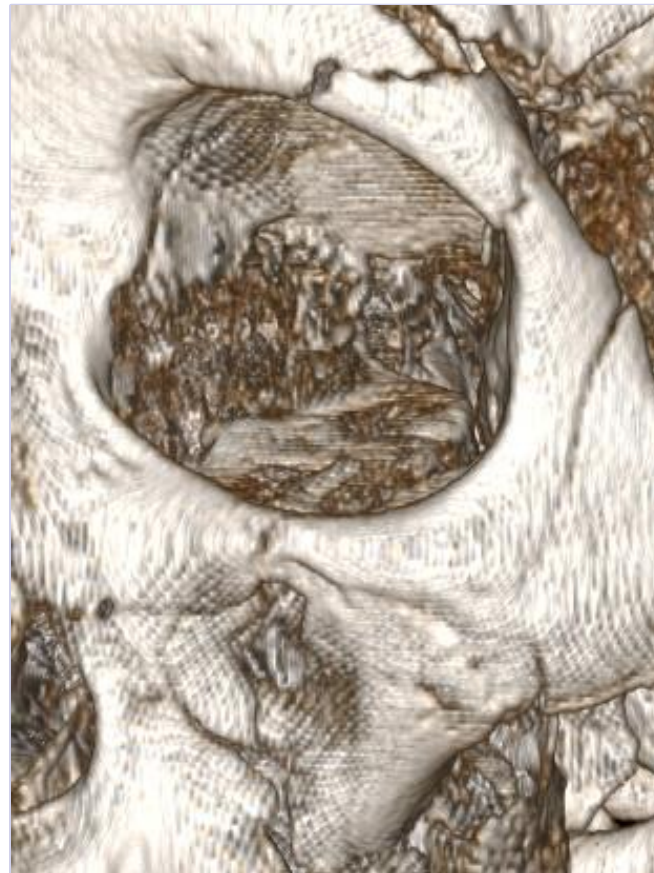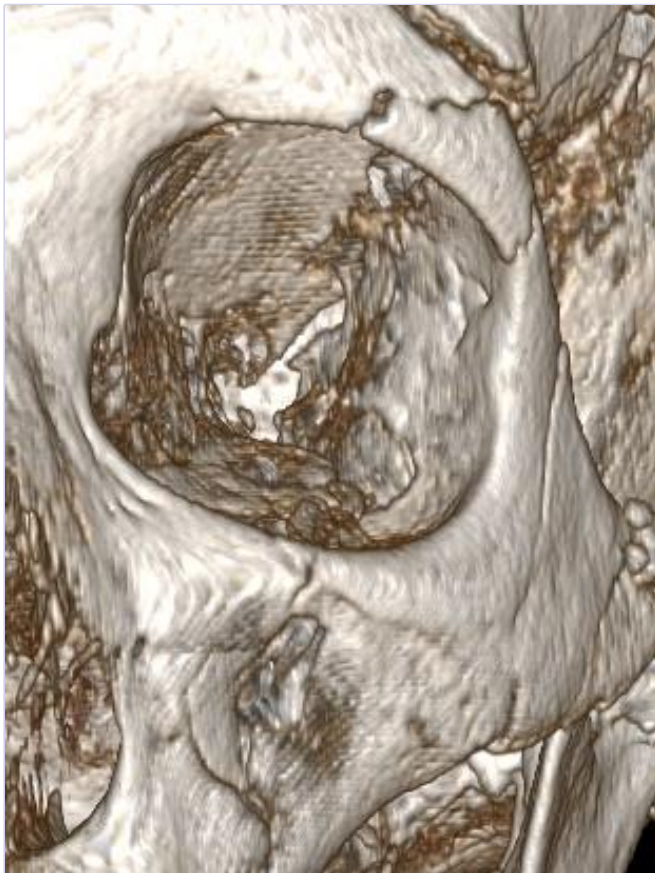


- Example: 1603315M

Master



- Example: 1609534R

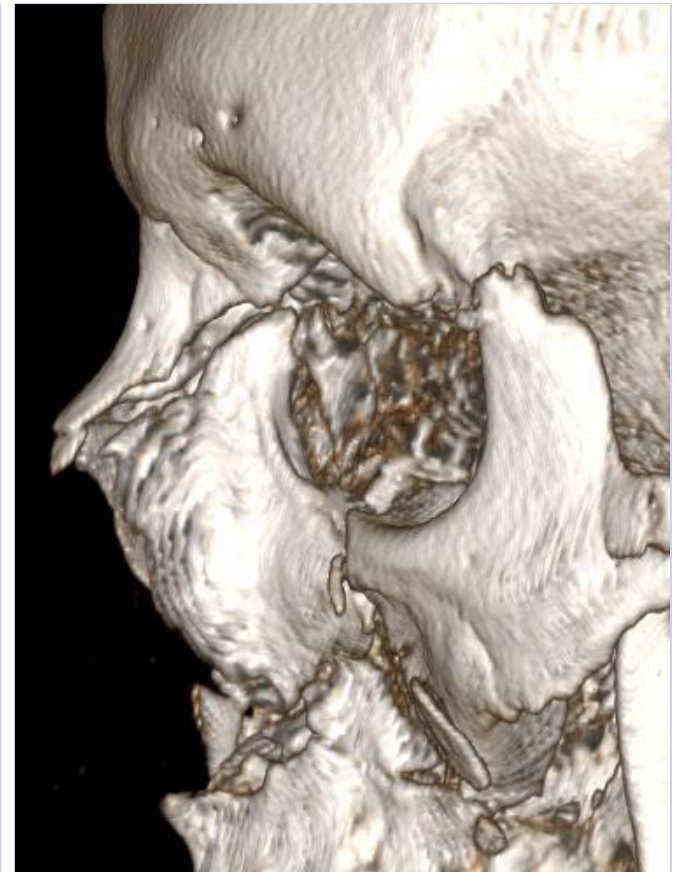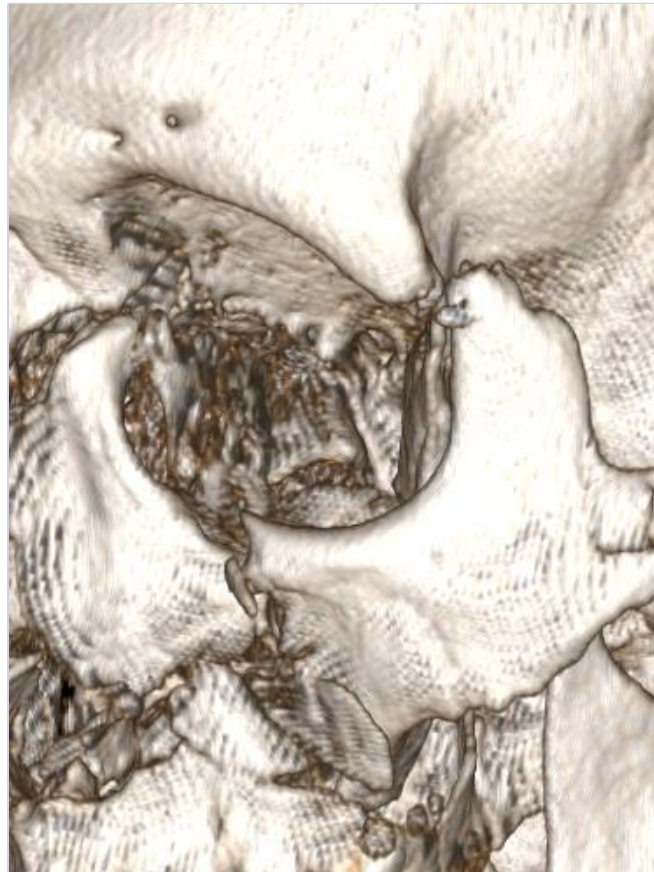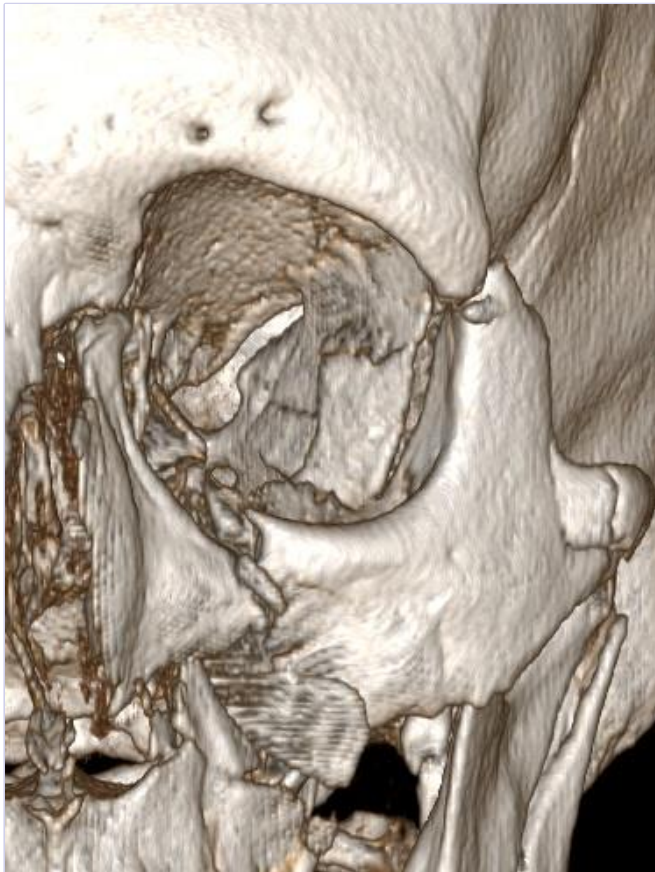


Sex: f

Age: 68

BMI: 25

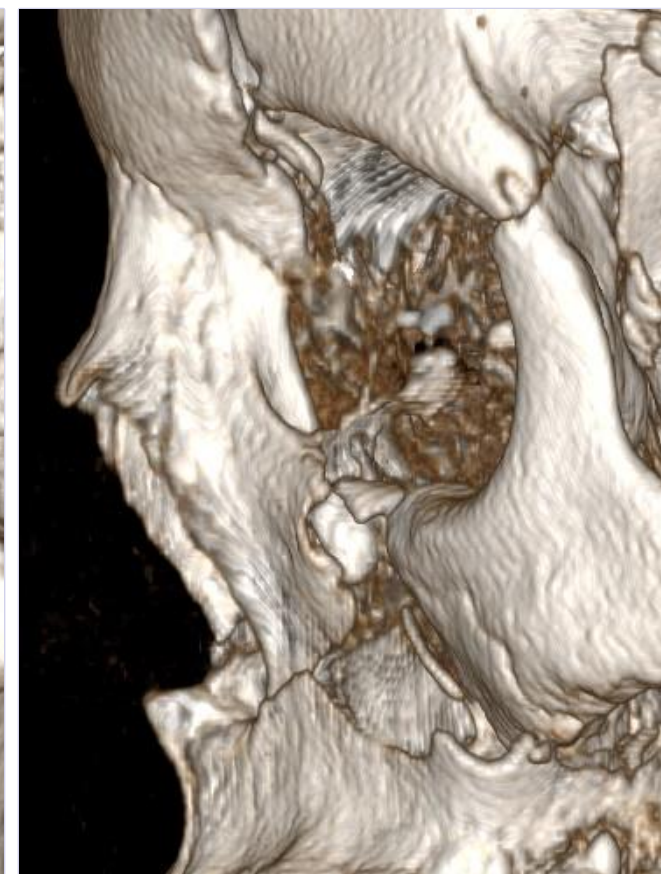
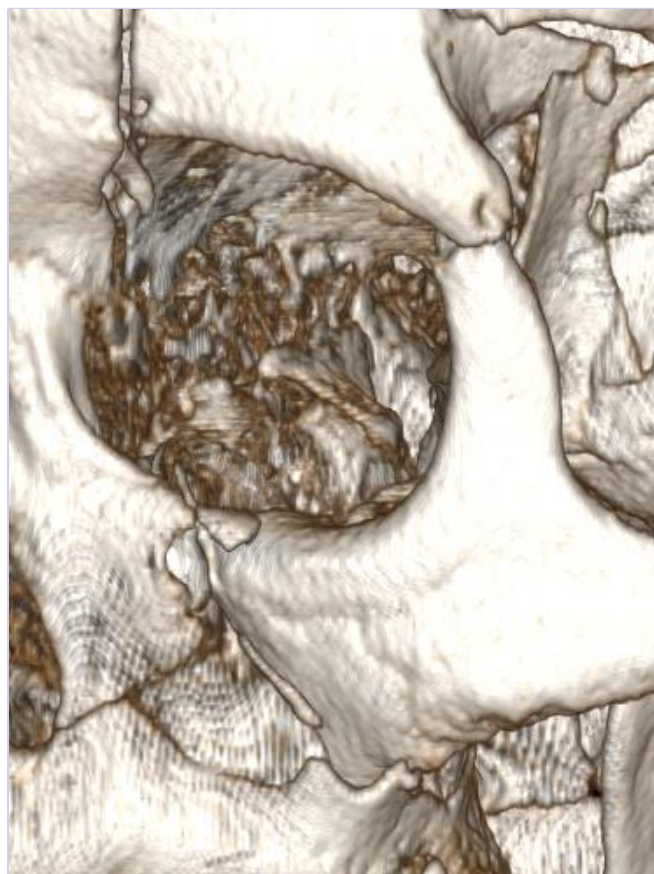
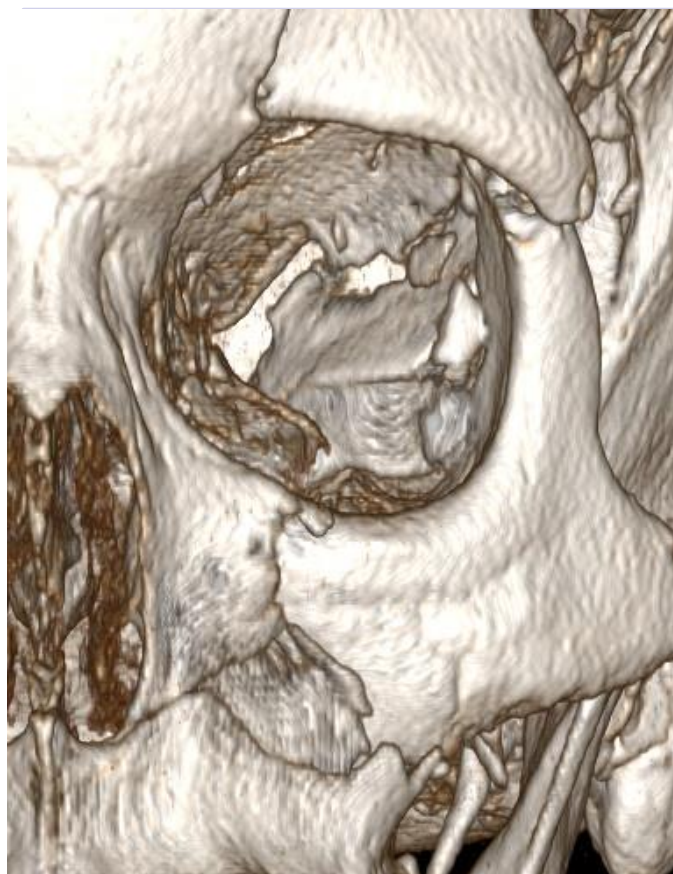
18/07/2018



Sex: m

Age: 37

BMI: 40



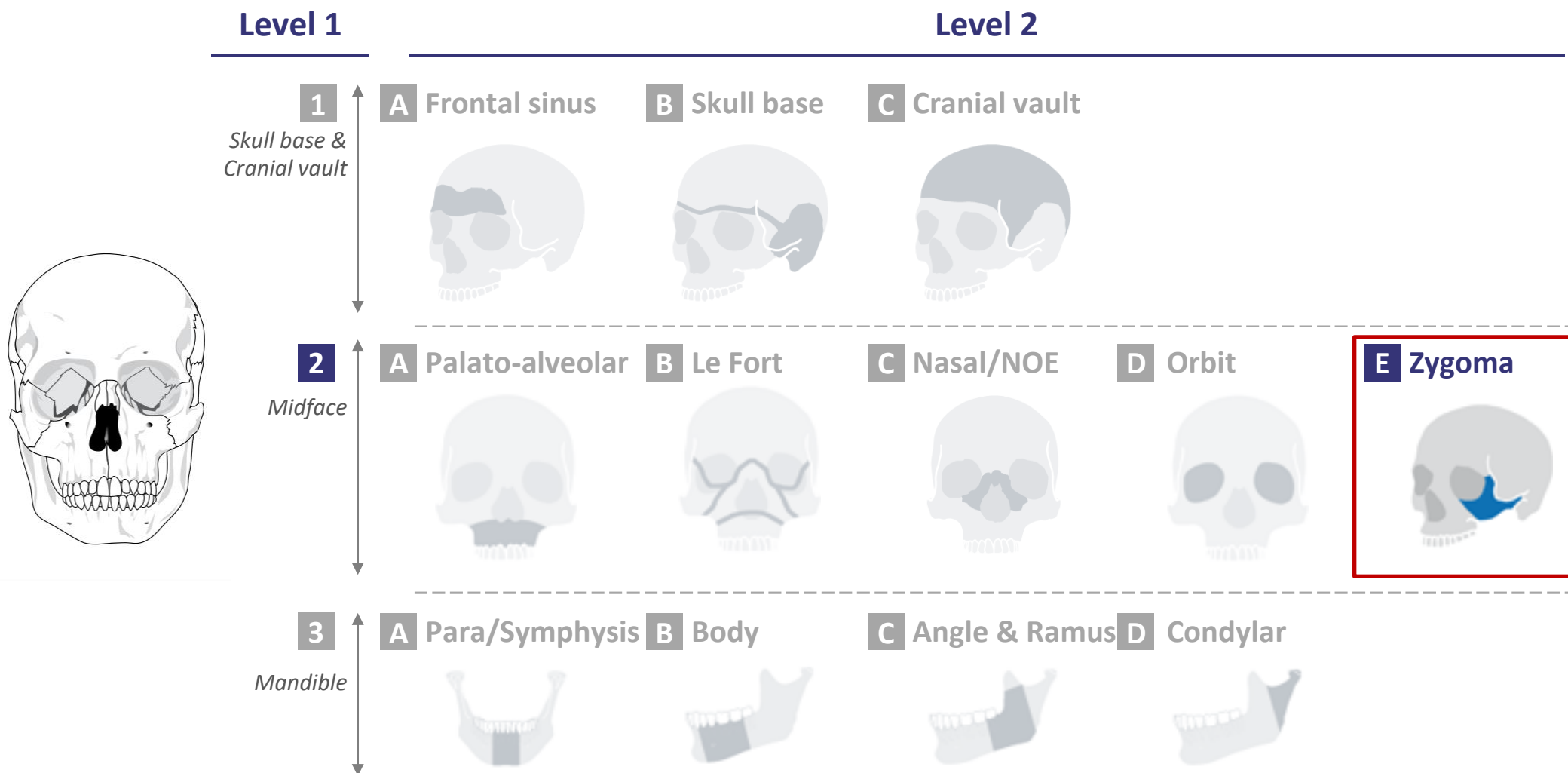
Sex: f

Age: 53

BMI: 32

18/07/2018

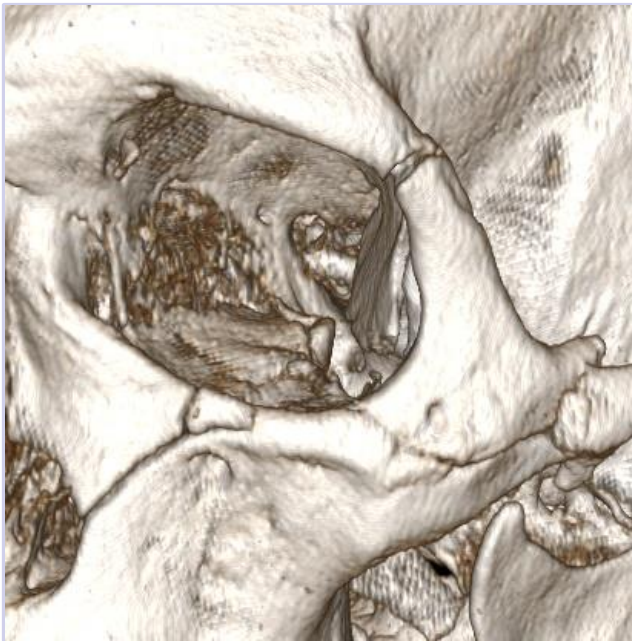CMF fracture portfolio: 2E-Zygoma





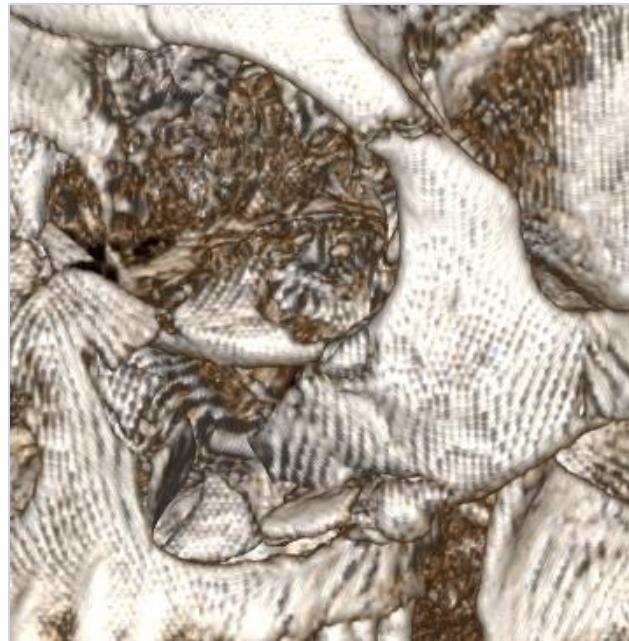level of complexity

Moderate



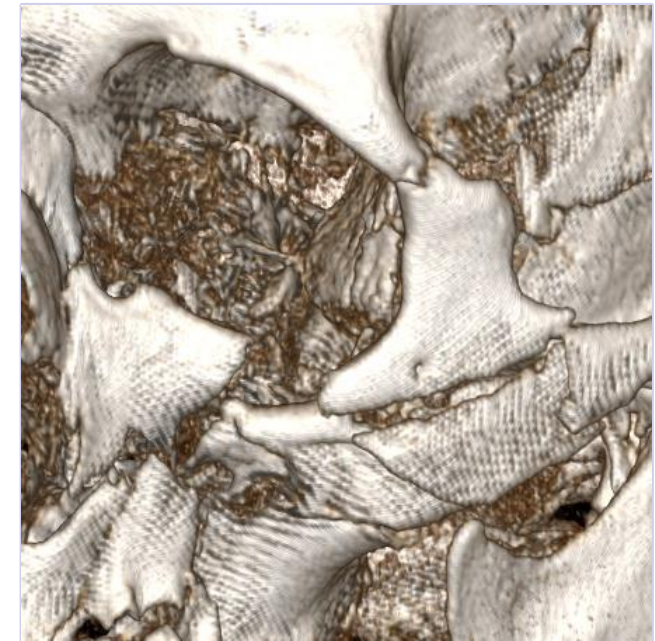- Example: 1603314M

Advanced

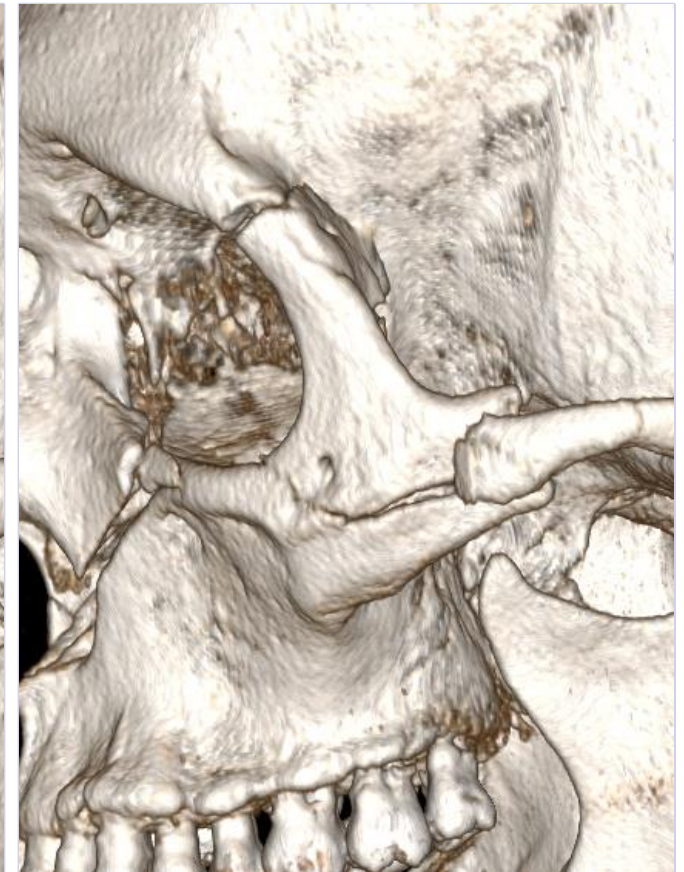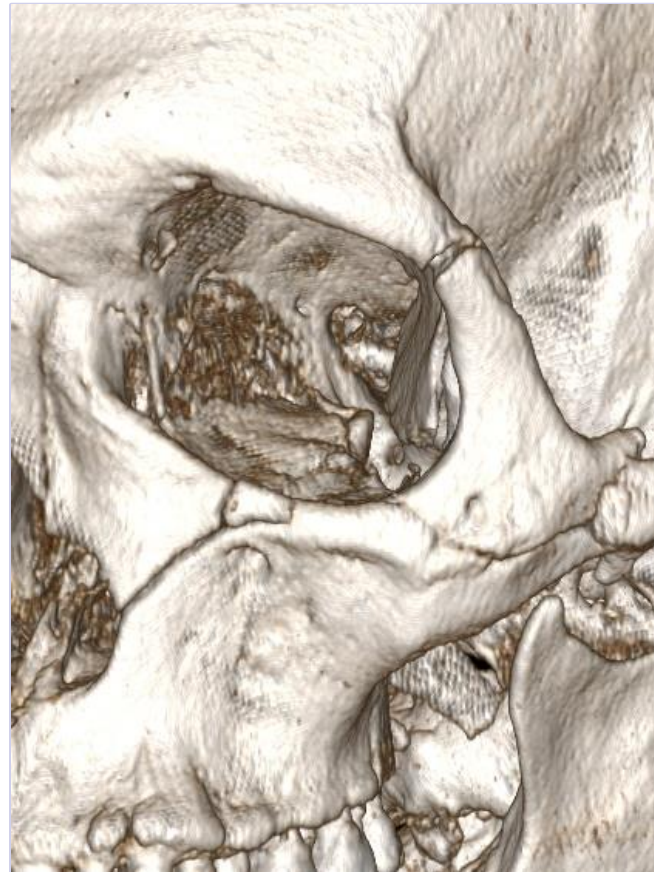

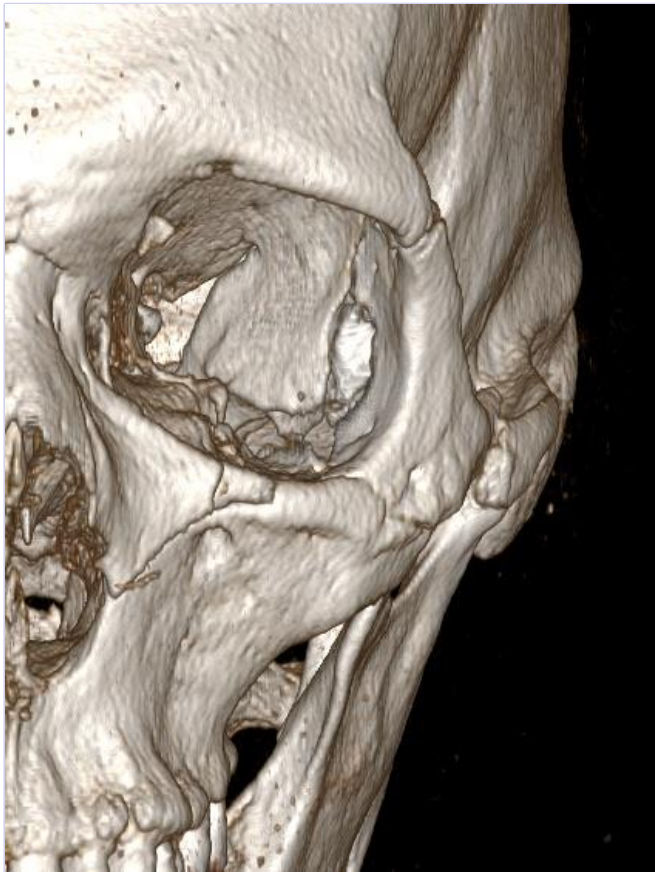
- Example: F180647

Master



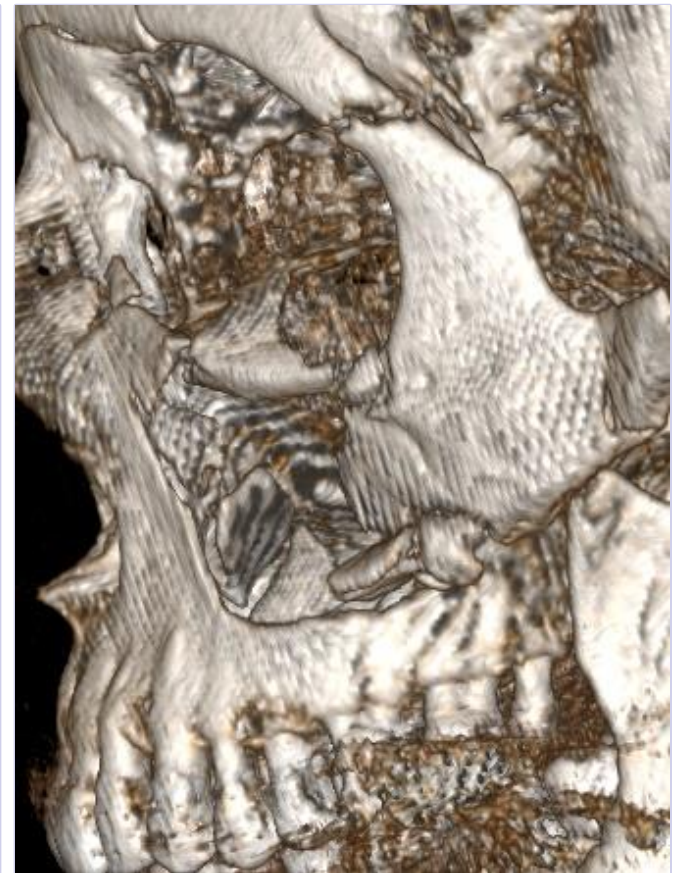
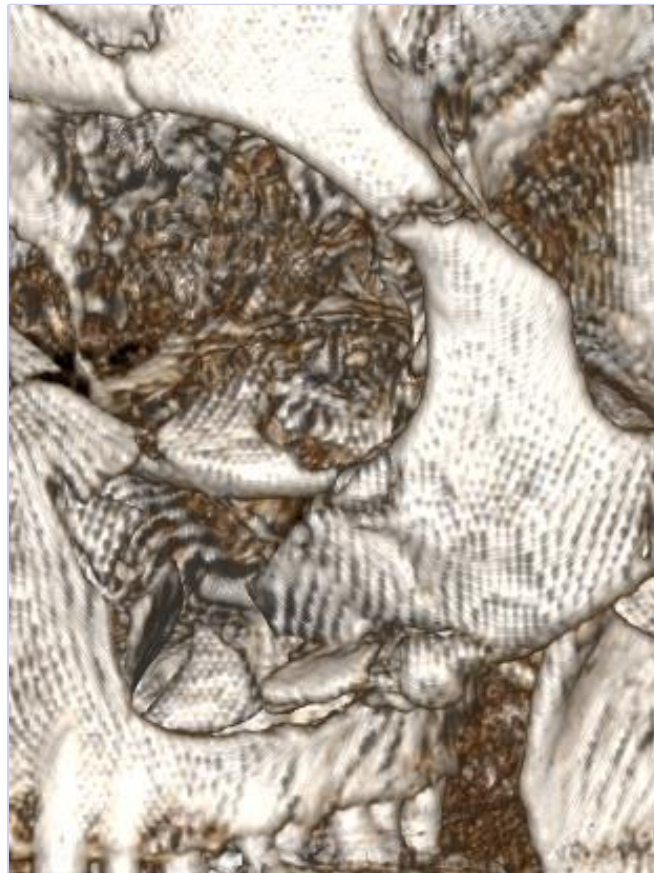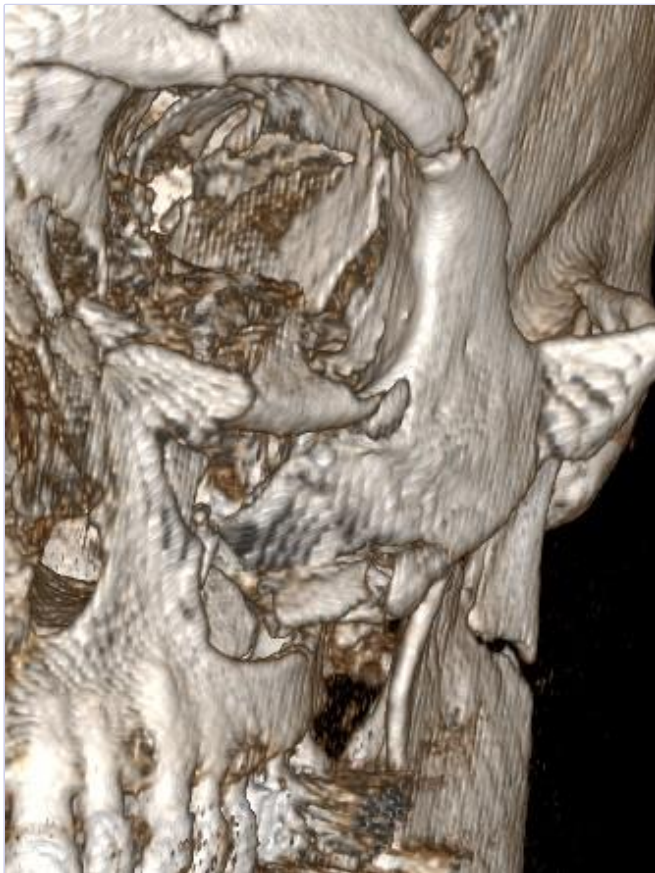- Example: F180655



Sex: m

Age: 61

BMI: 28

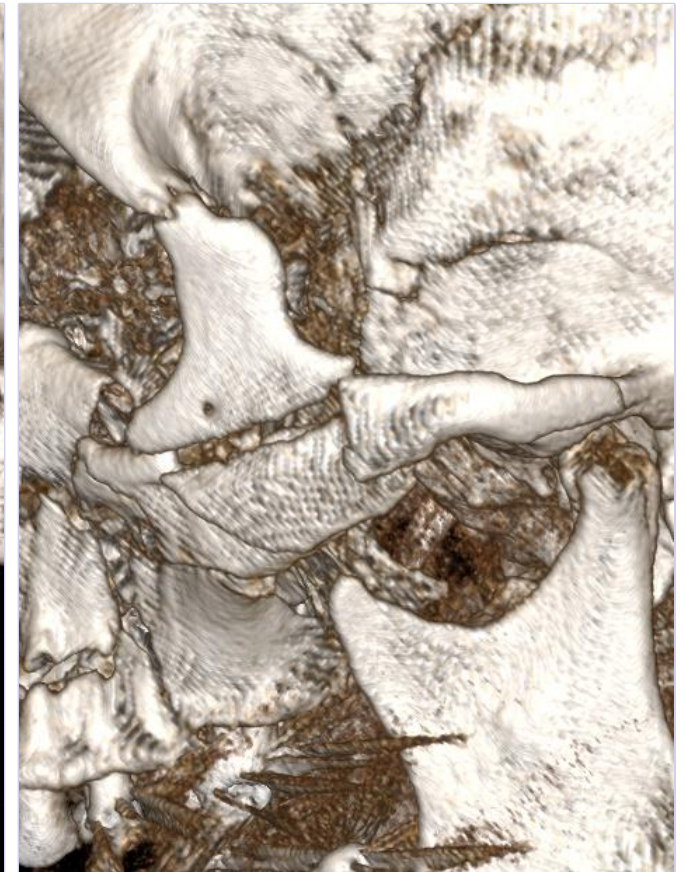
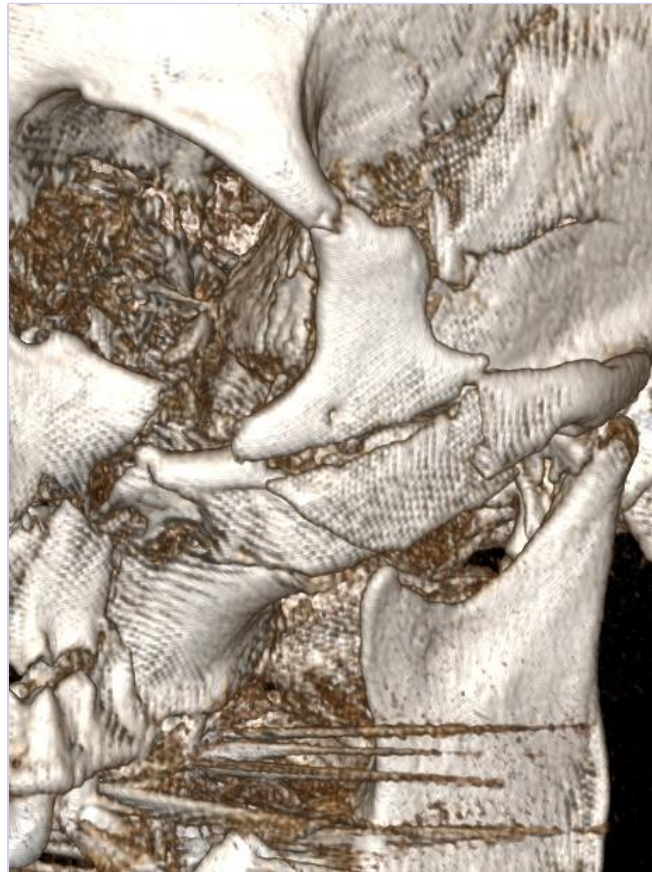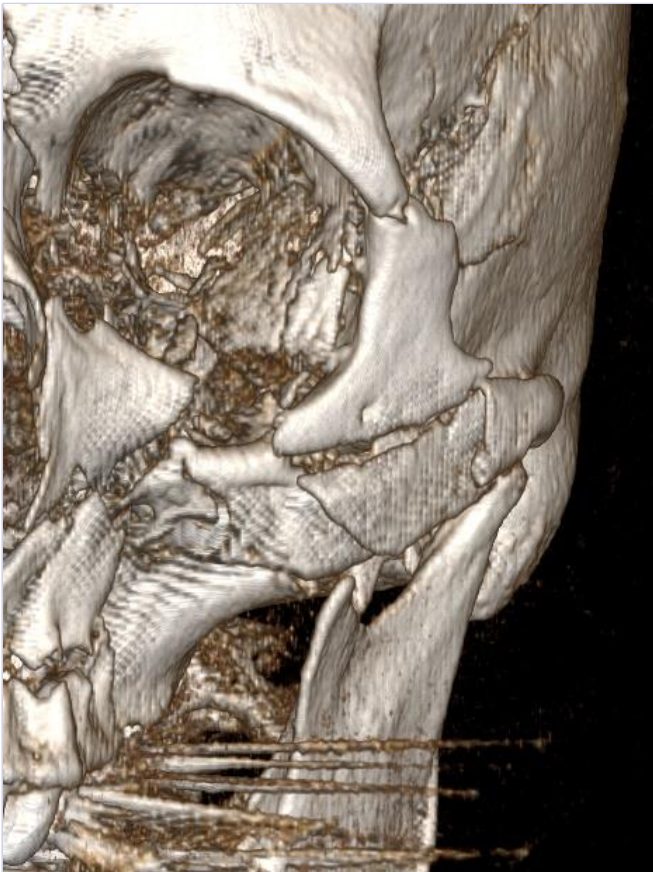


Sex: f

Age: 80

BMI: 23

18/07/2018

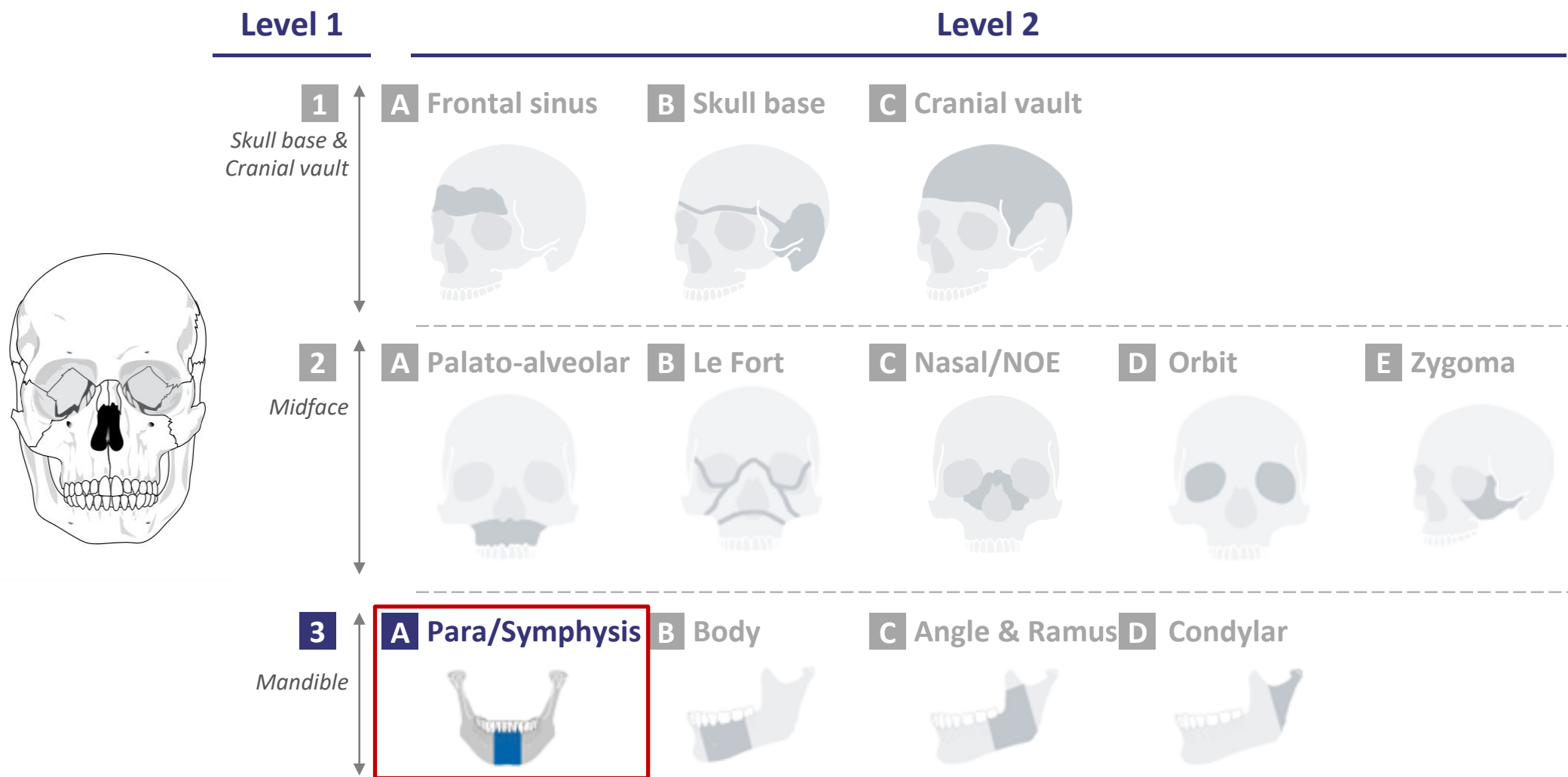


Sex: m

Age: 65

BMI: 24

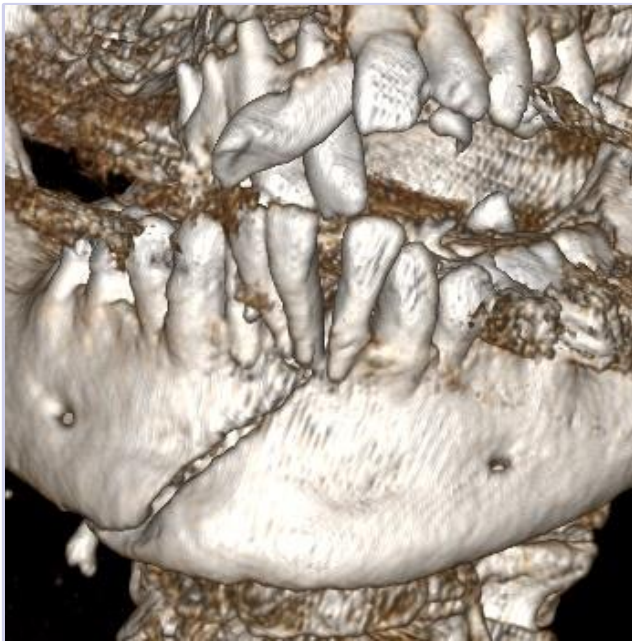
CMF fracture portfolio: 3A-Para/Symphysis





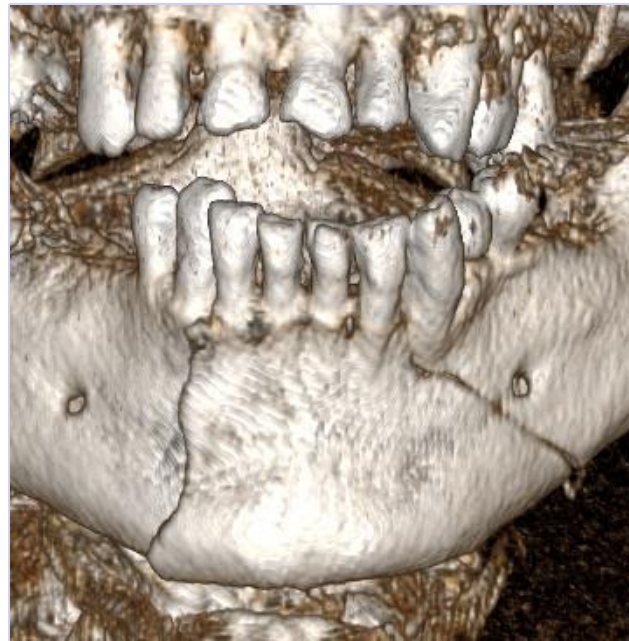level of complexity

Moderate



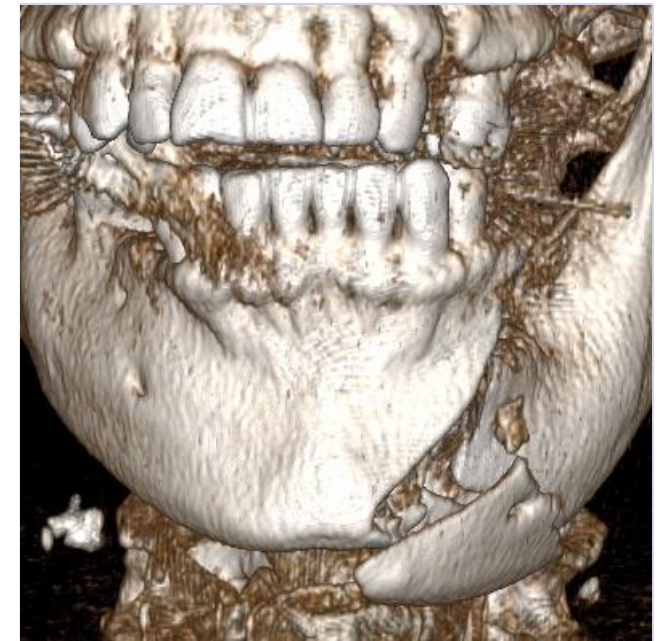- Example: F180754

Advanced

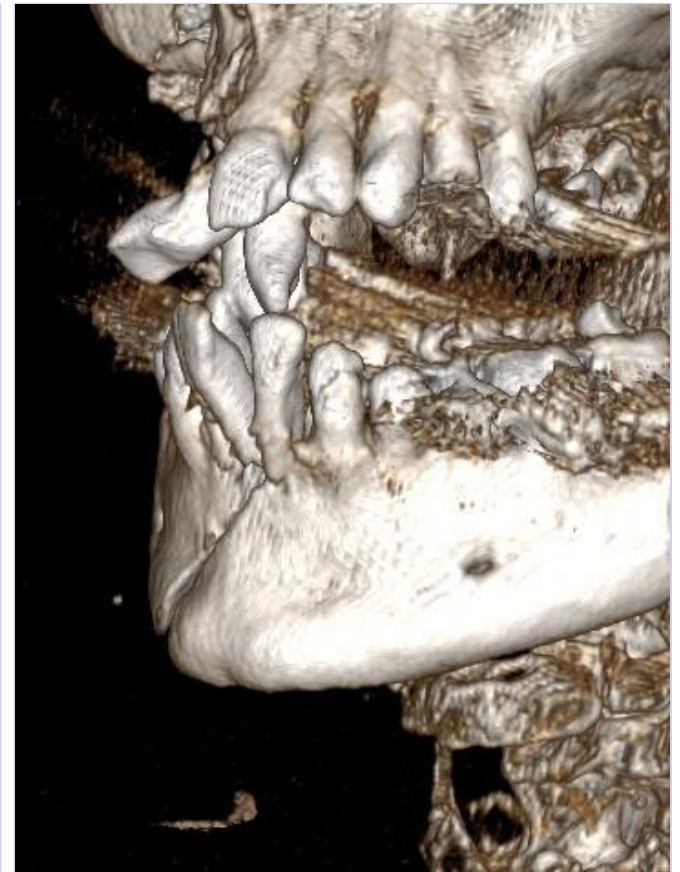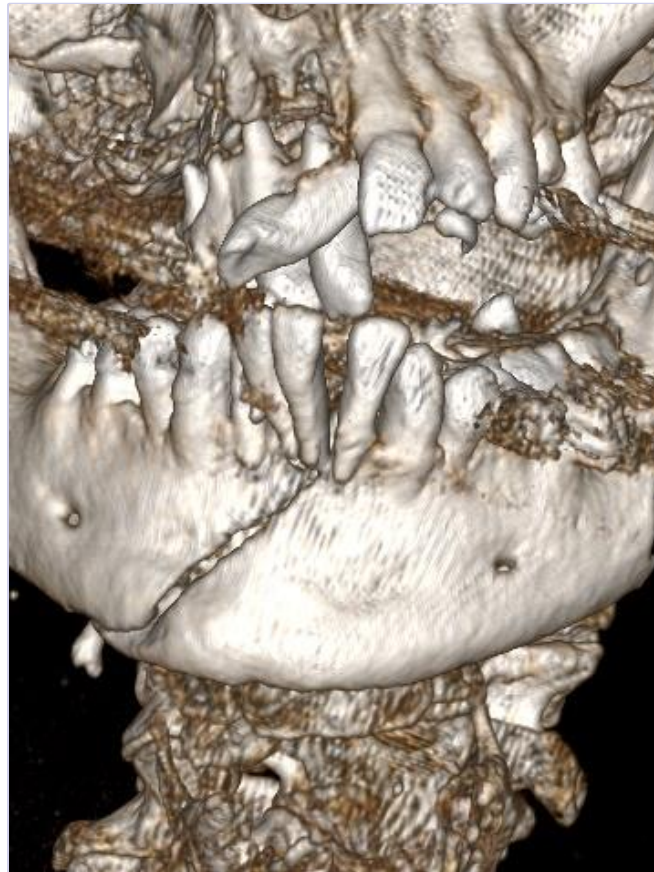

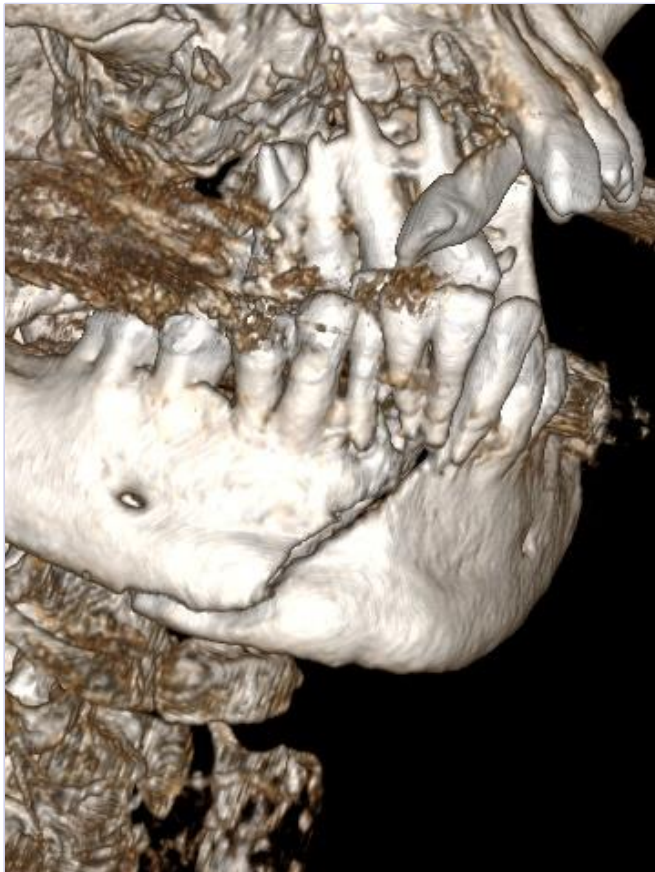
- Example: F180604

Master



- Example: F180677

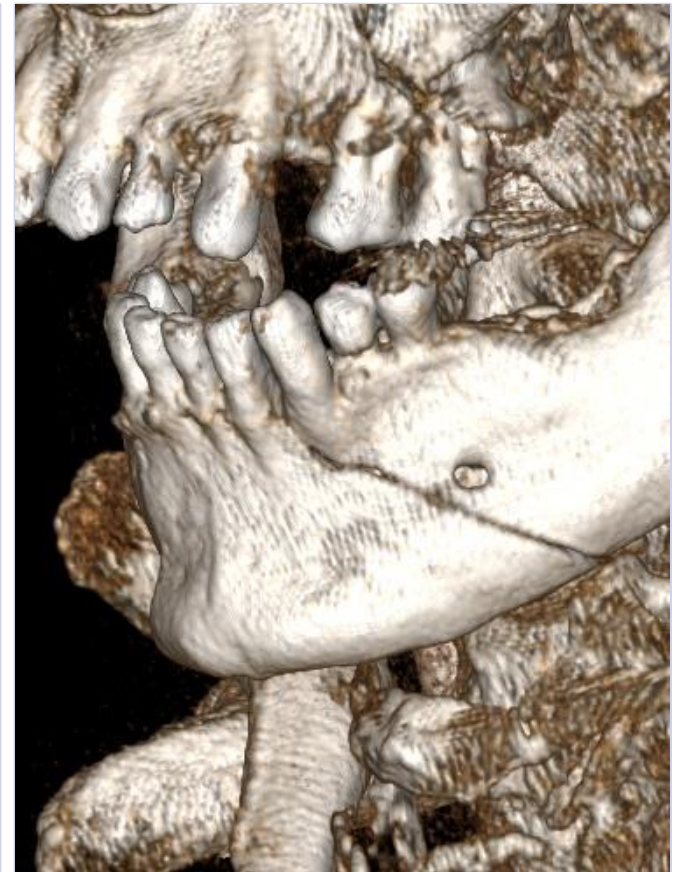
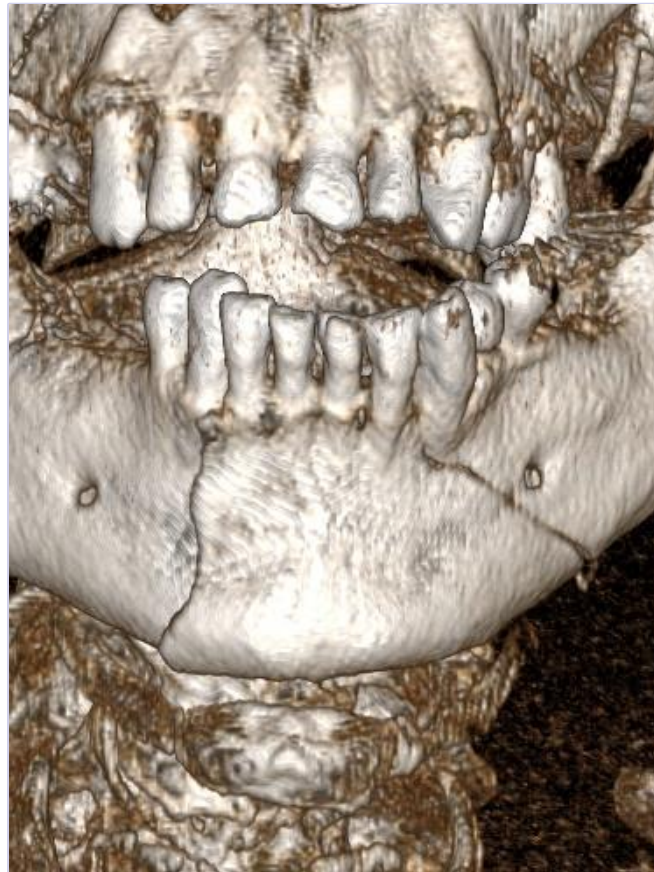
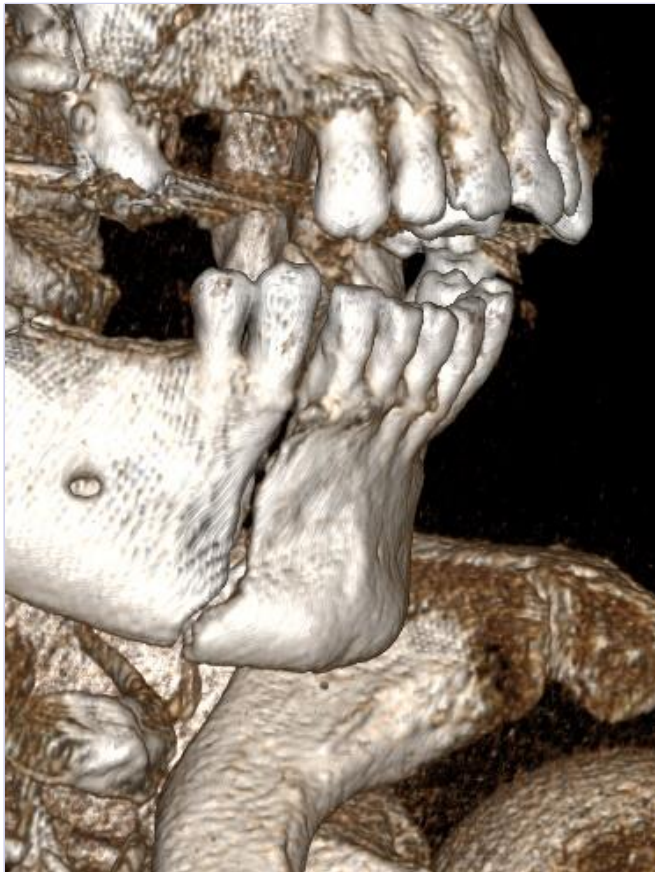
Sex: f

Age: 69

BMI: 21

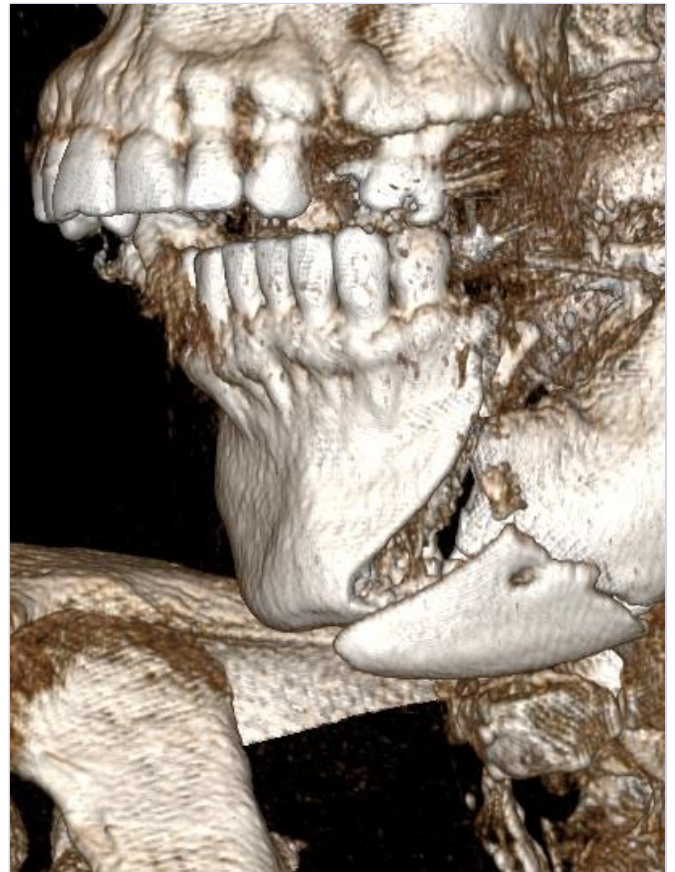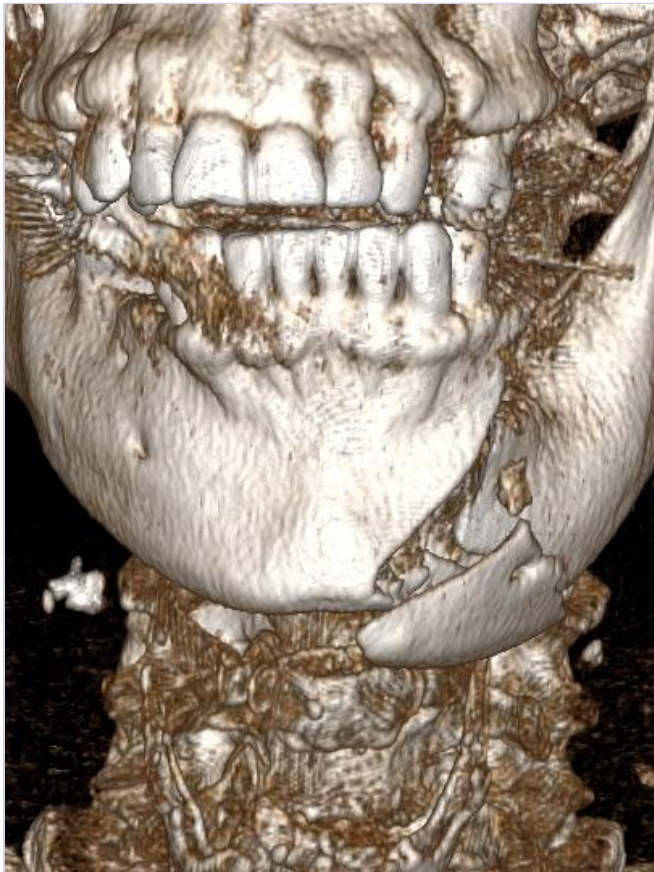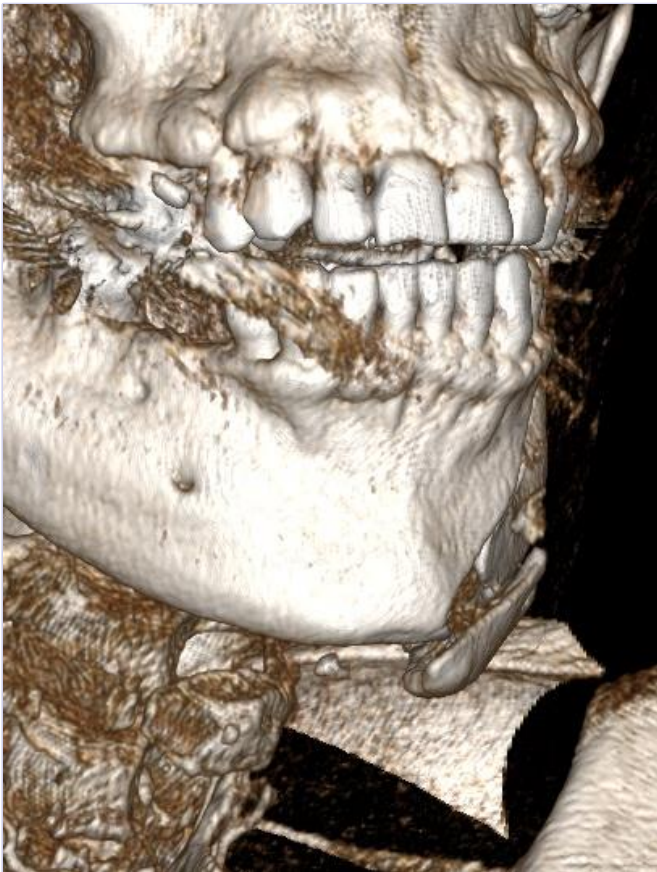18/07/2018



Sex: m

Age: 76

BMI: 23



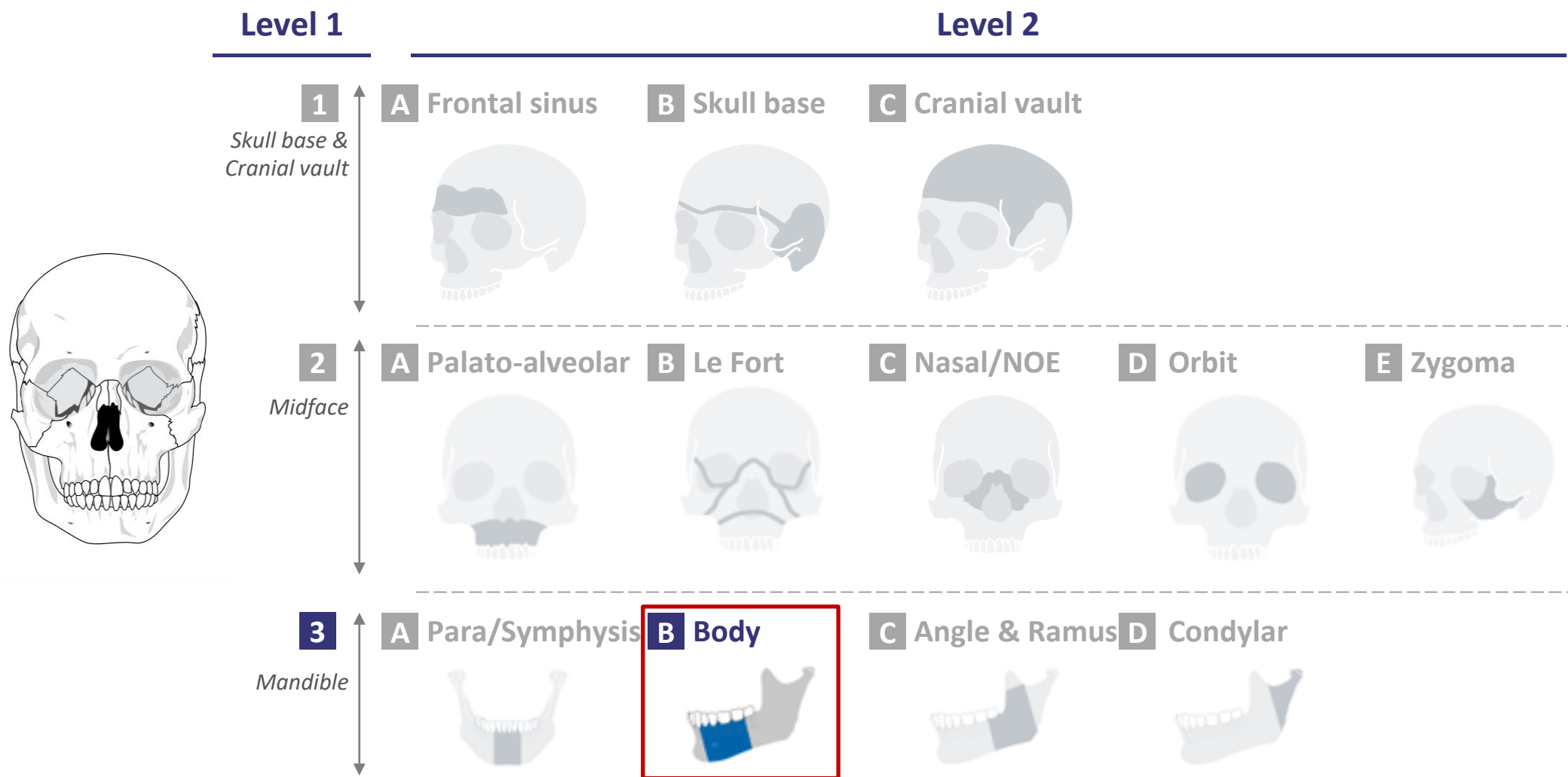
Sex: f

Age: 61

BMI: 24

18/07/2018

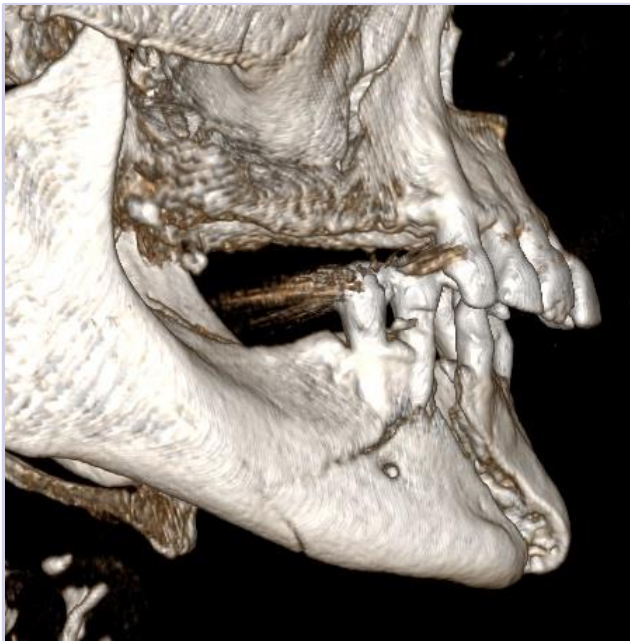CMF fracture portfolio: 3B-Body





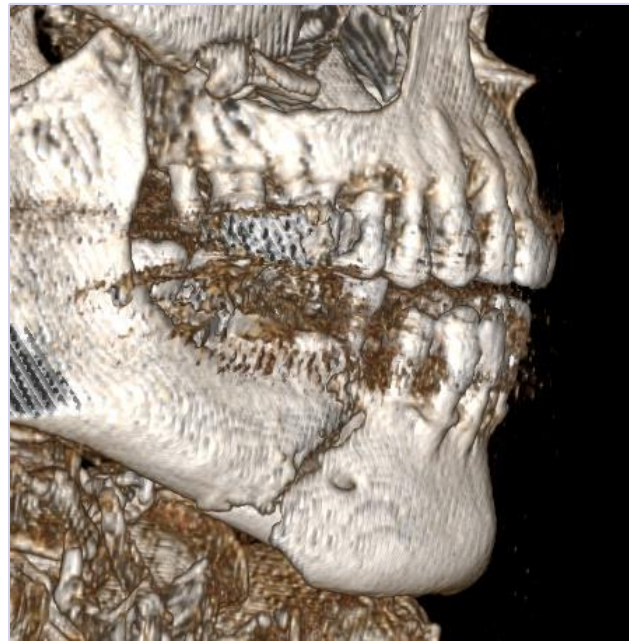level of complexity

Moderate



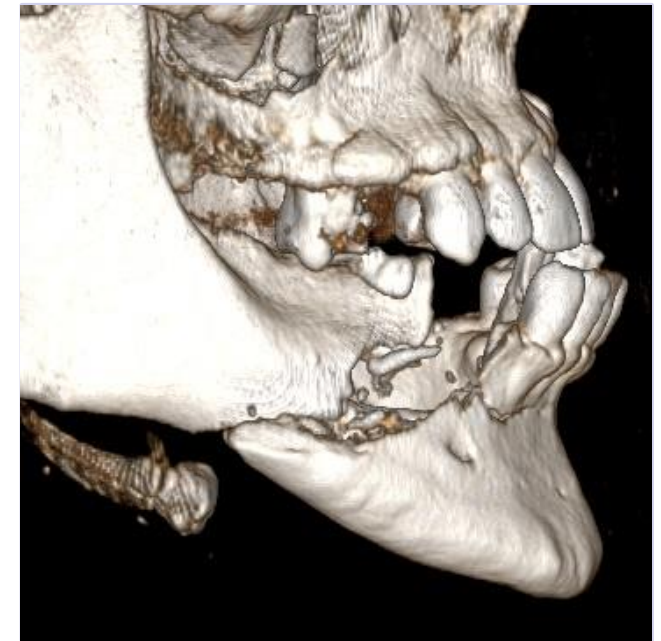- Example: 1702045M

Advanced

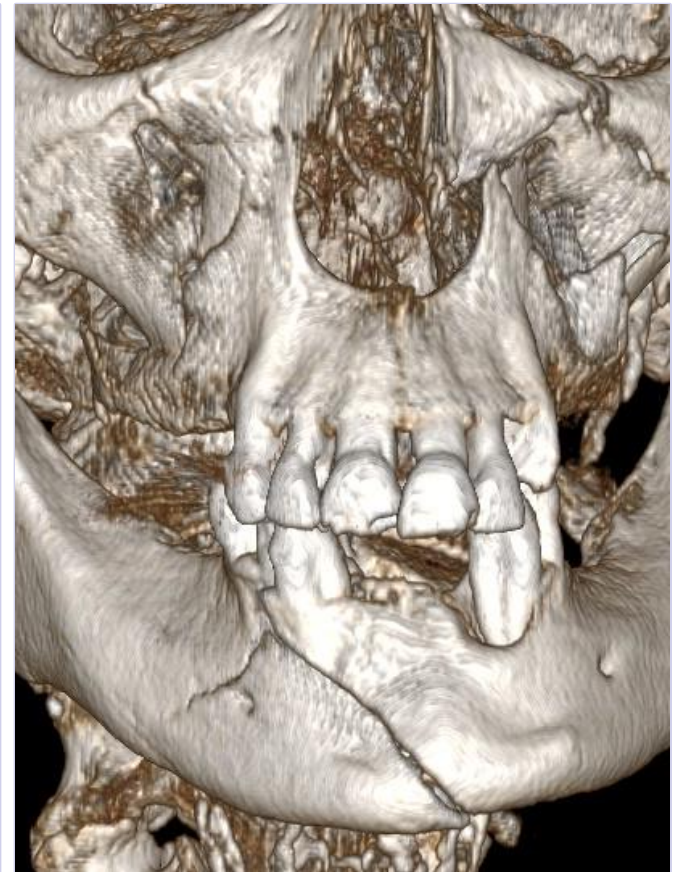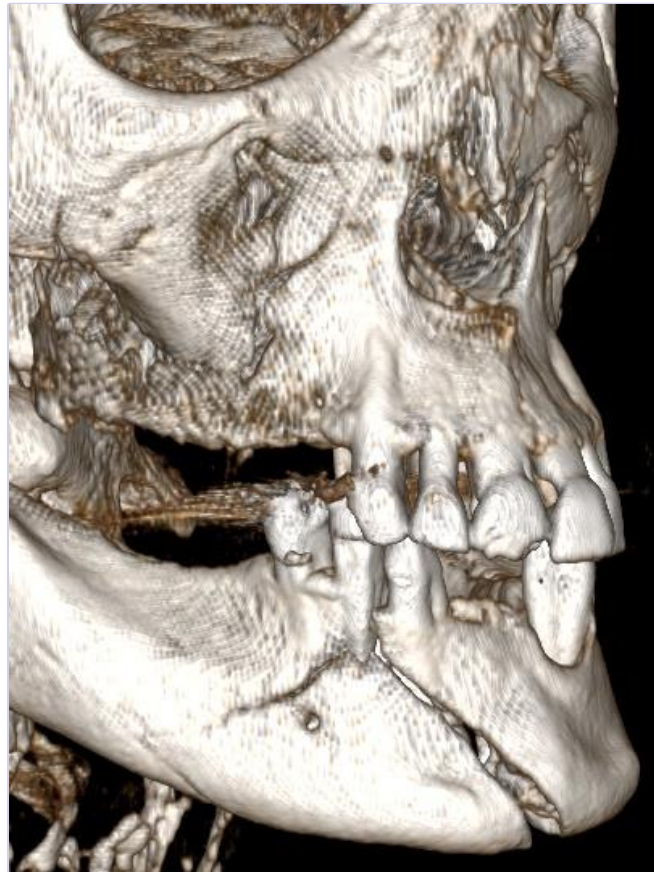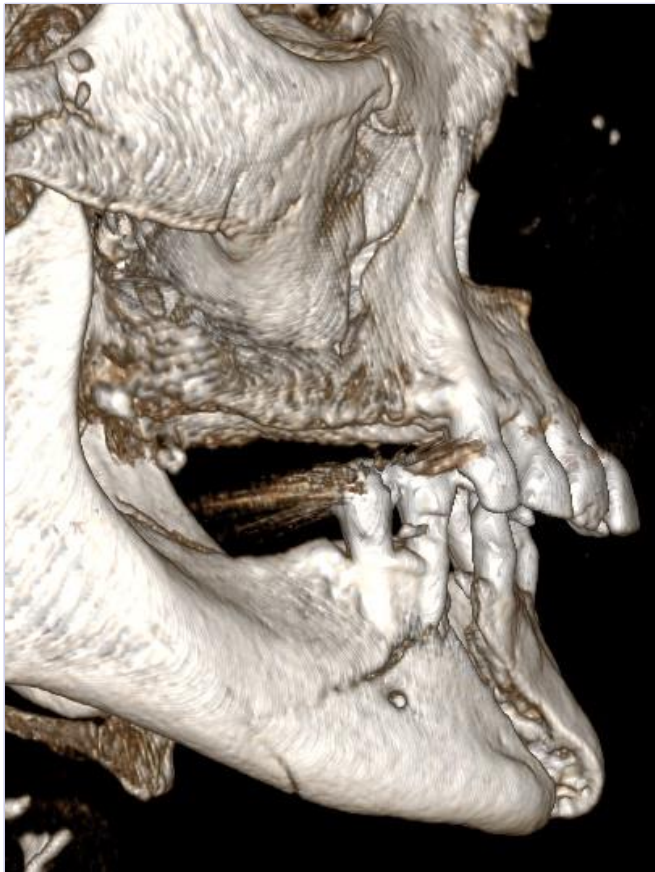


- Example: F180647

Master



- Example: 1609534R

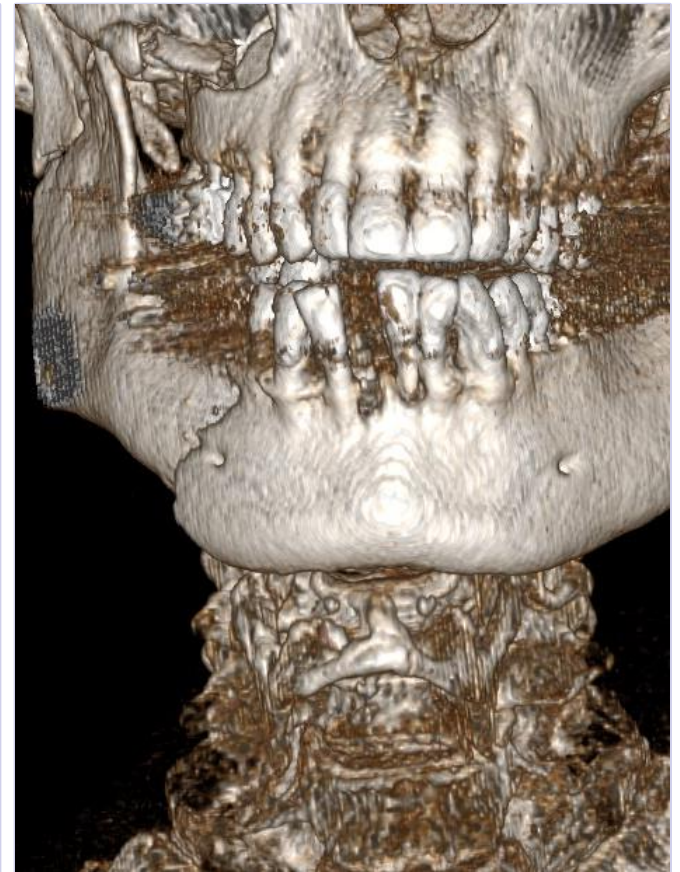
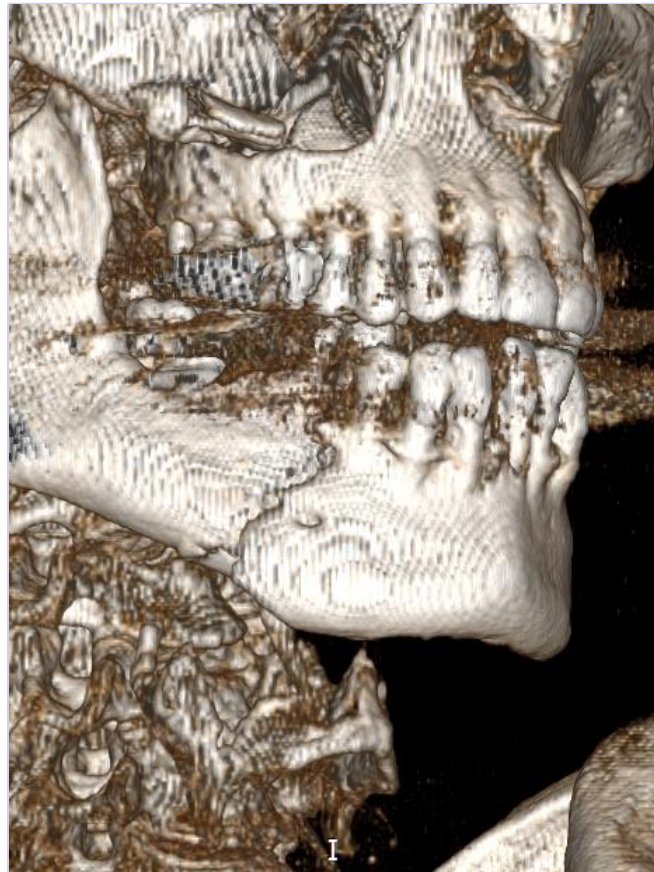
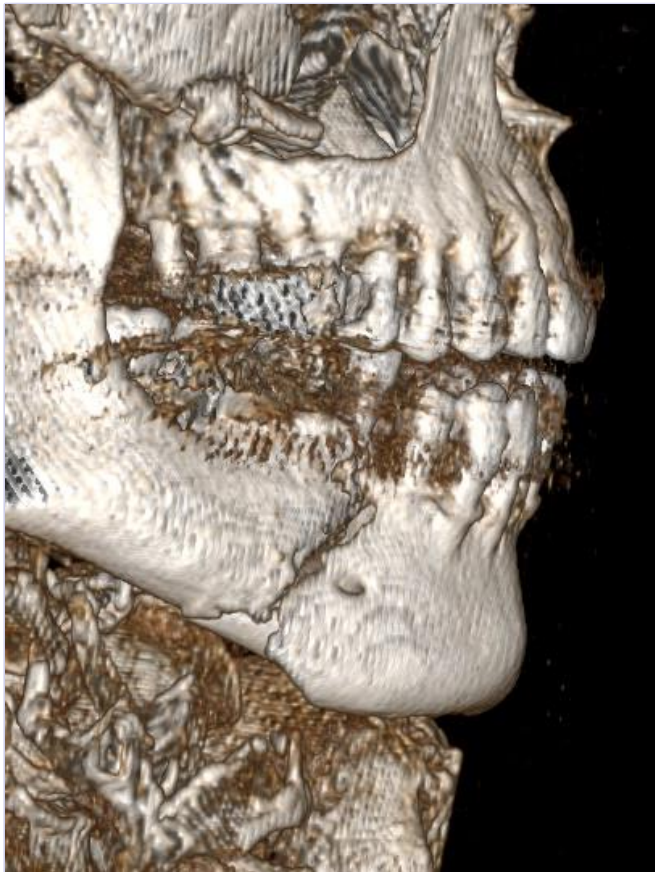

Sex: f

Age: 68

BMI: 25

18/07/2018

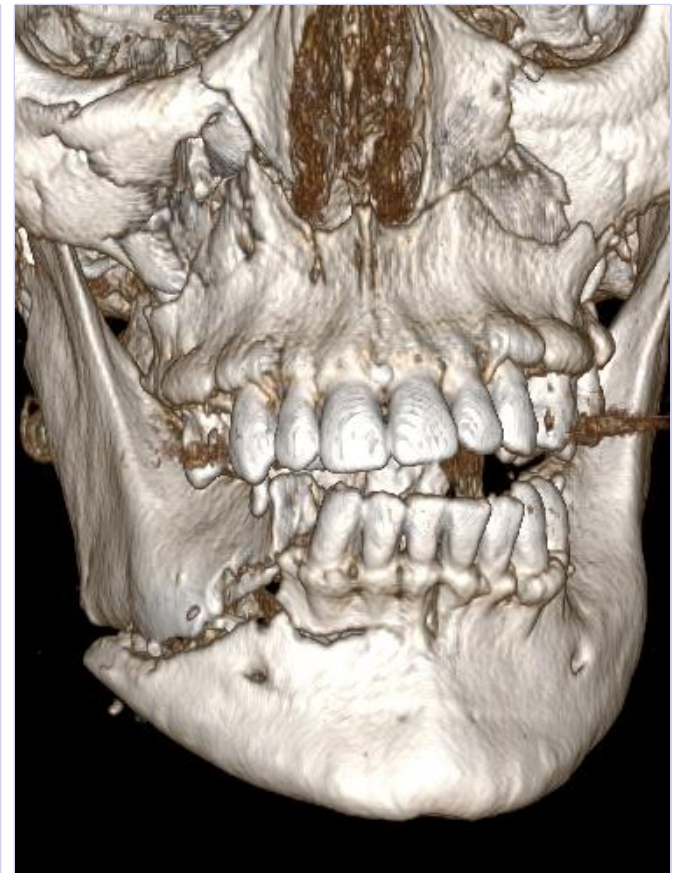
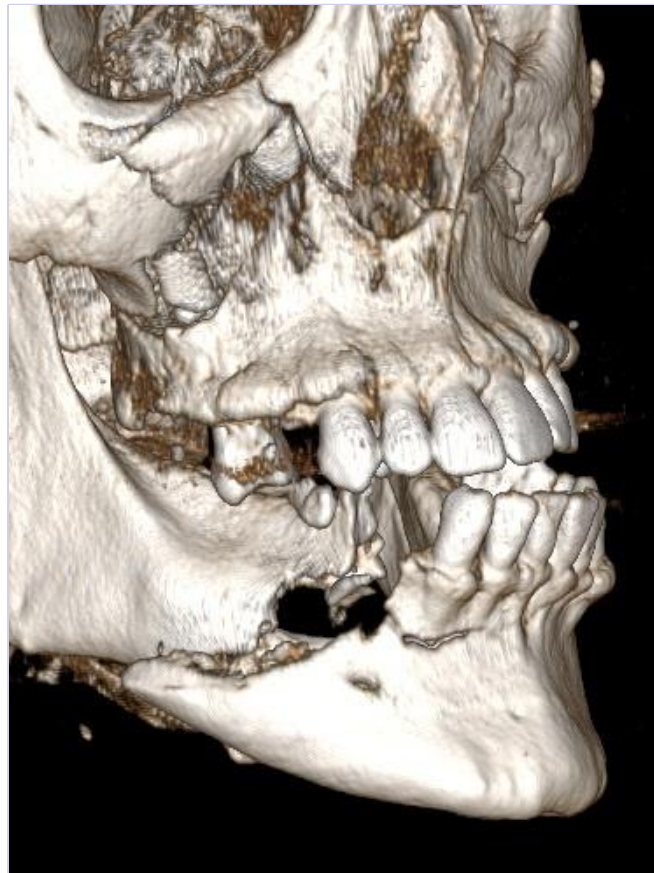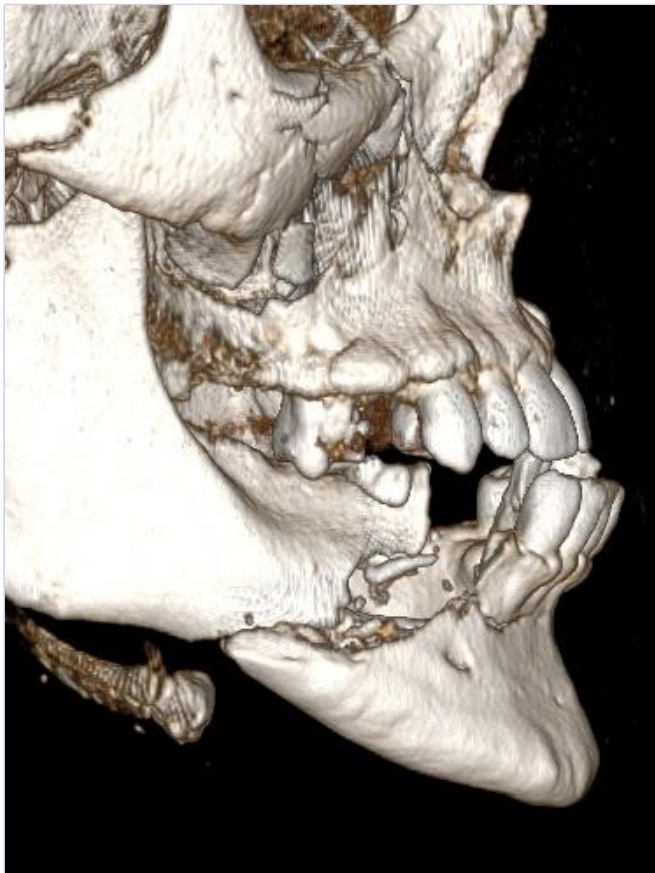


Sex: f

Age: 80

BMI: 23

18/07/2018



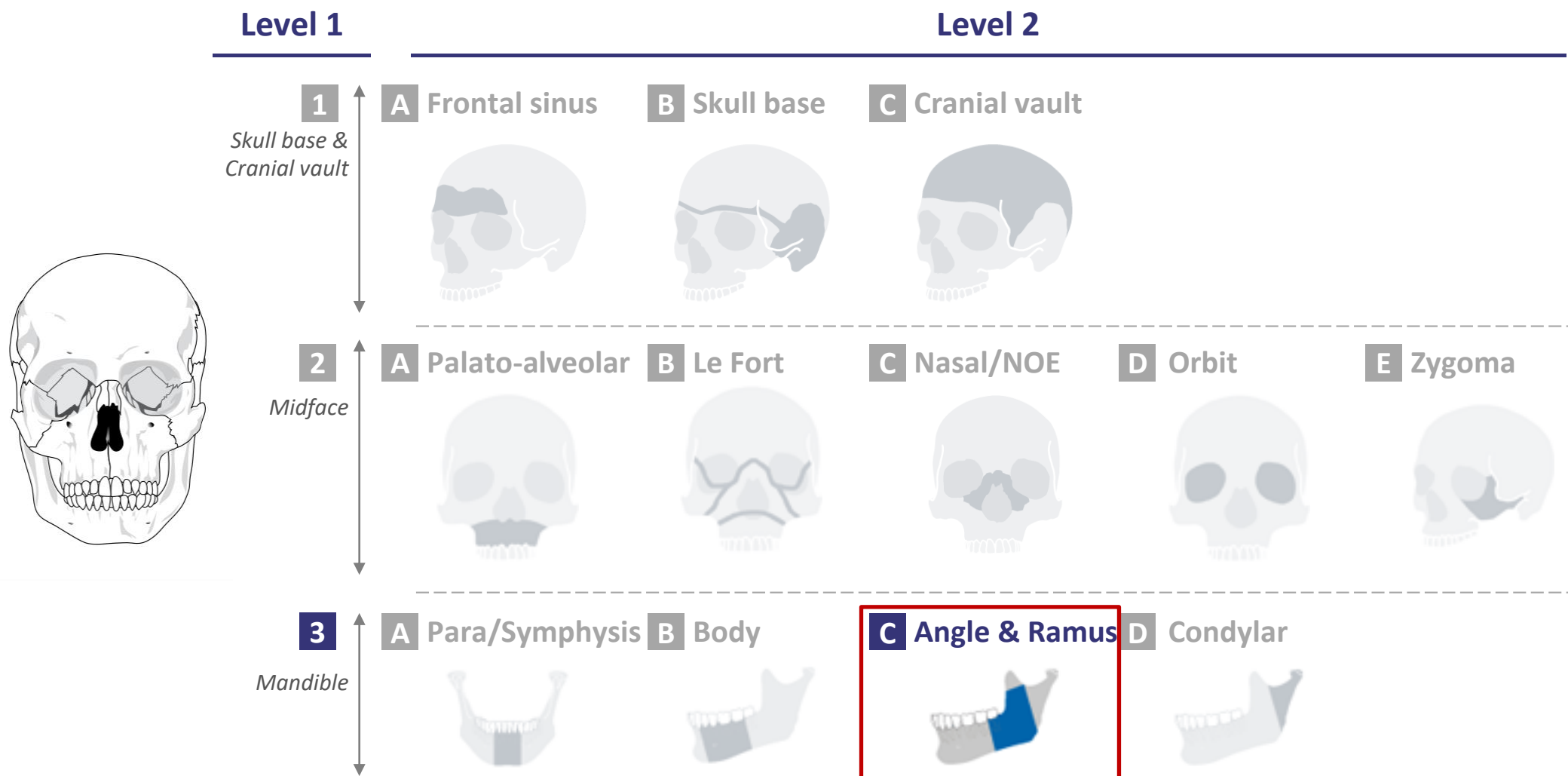
Sex: f

Age: 53

BMI: 32

18/07/2018

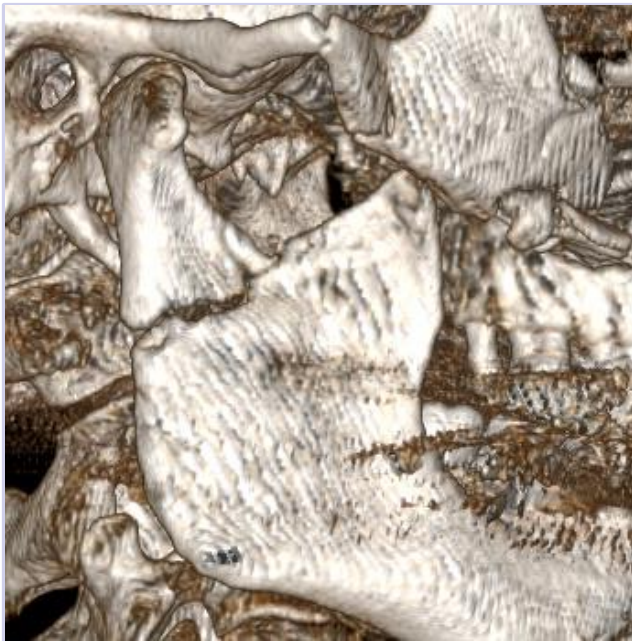CMF fracture portfolio: 3C-Angle&Ramus





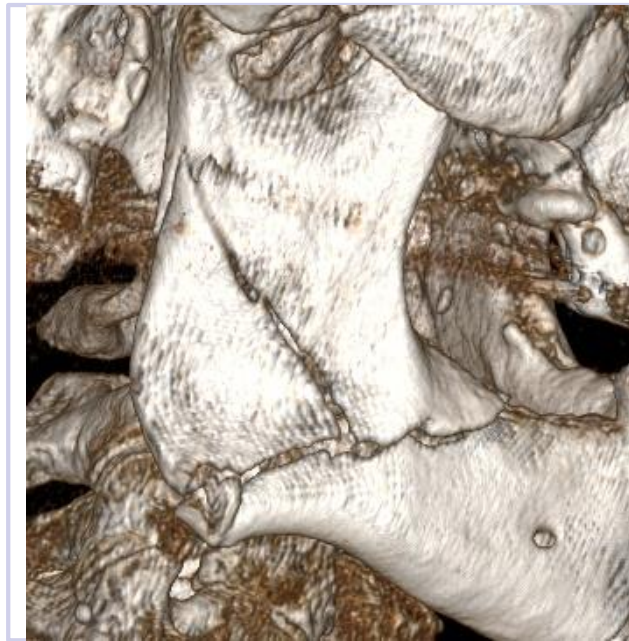
level of complexity

Moderate



- Example: F180647

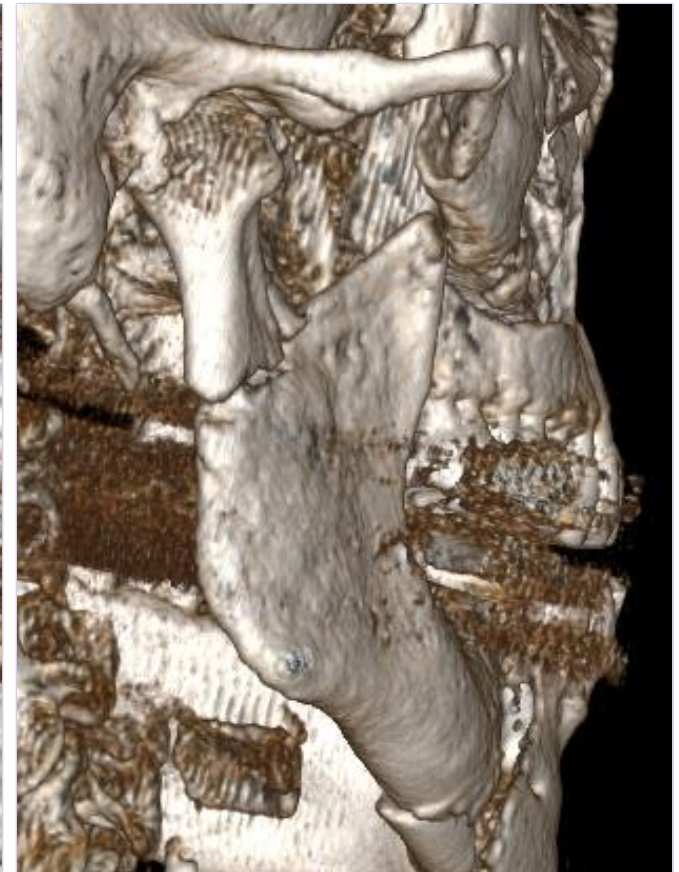
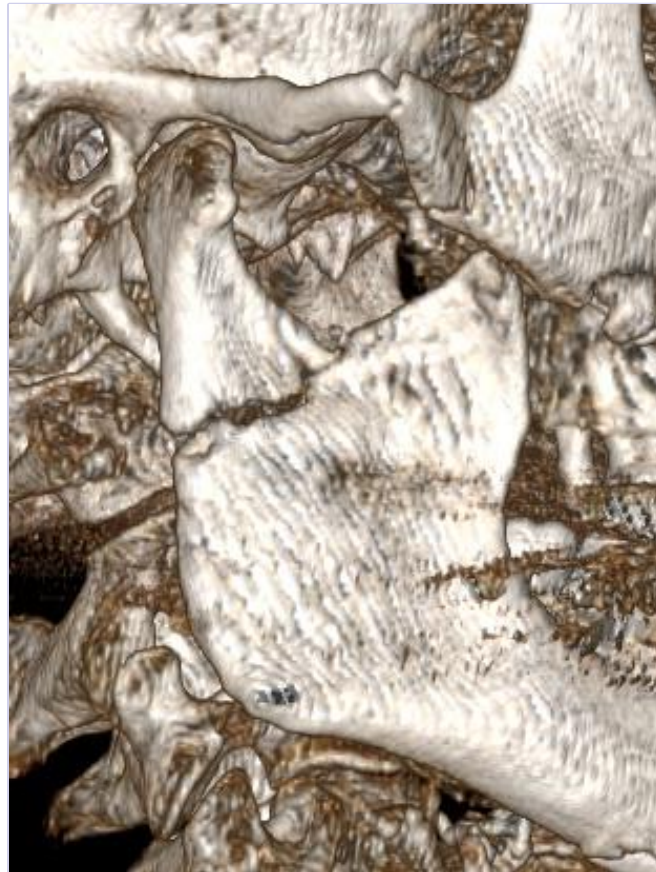
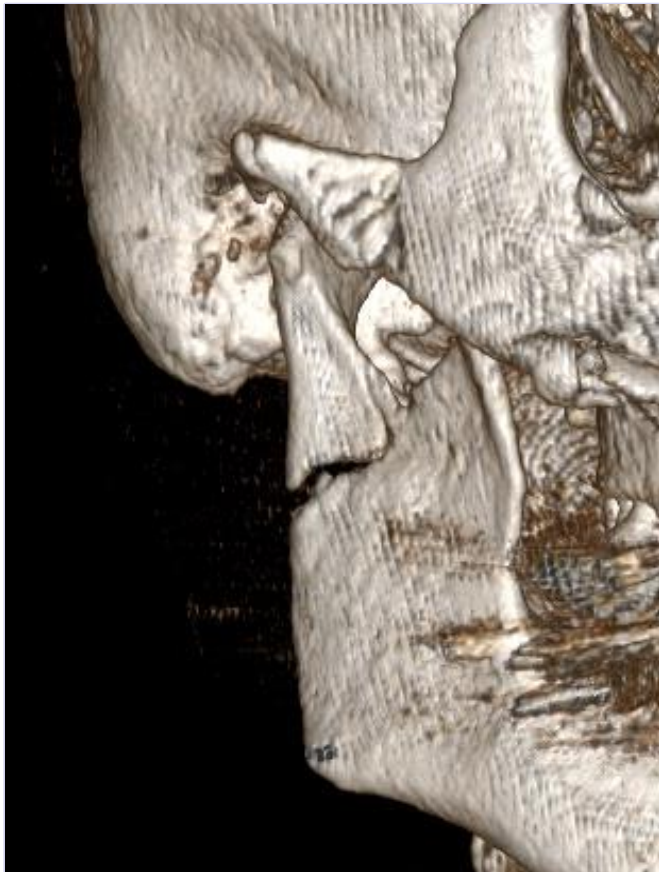
Advanced



- Example: F180604

Master

No CT scan available yet

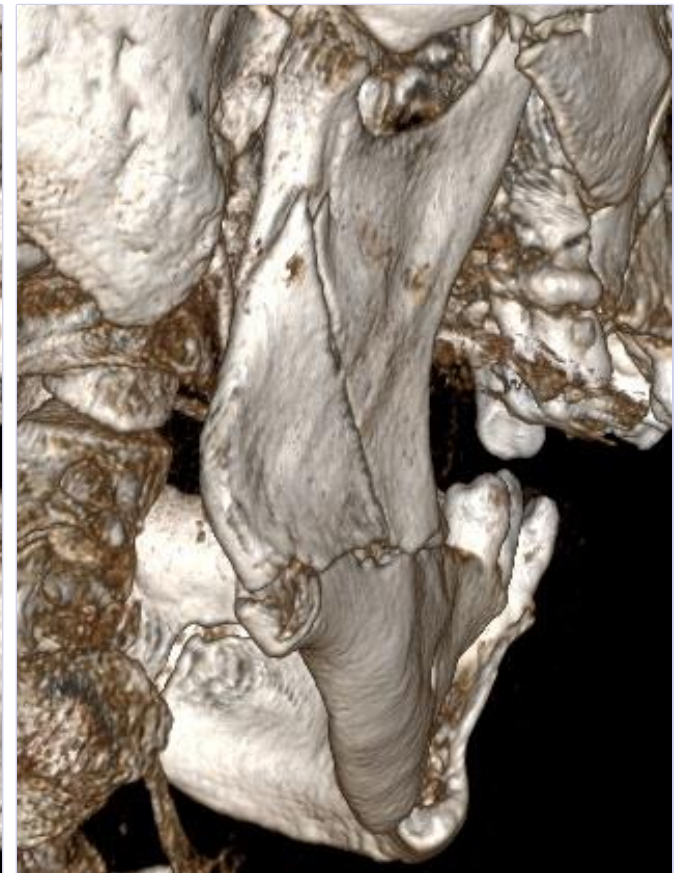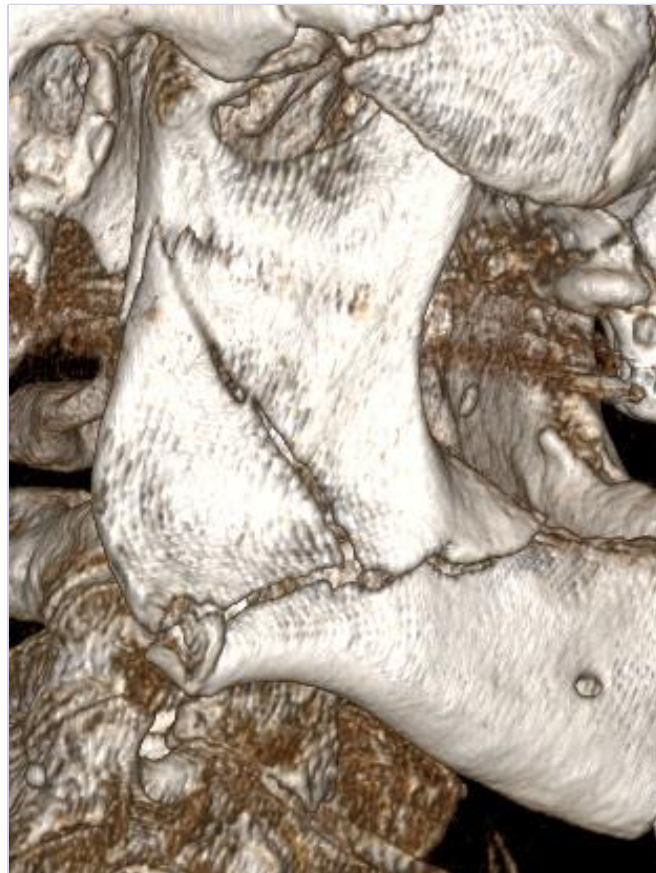

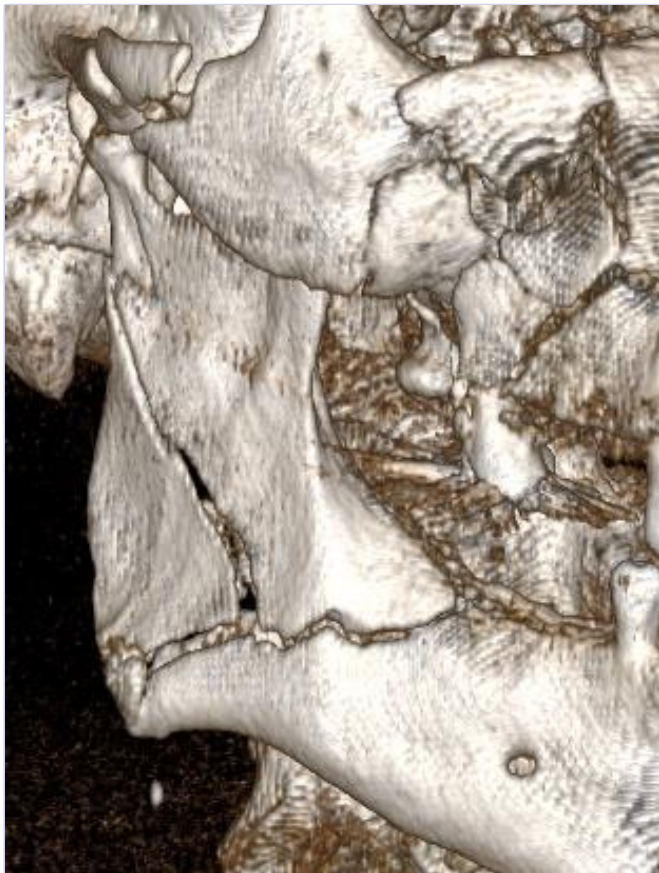
Sex: f

Age: 80

BMI: 23

18/07/2018



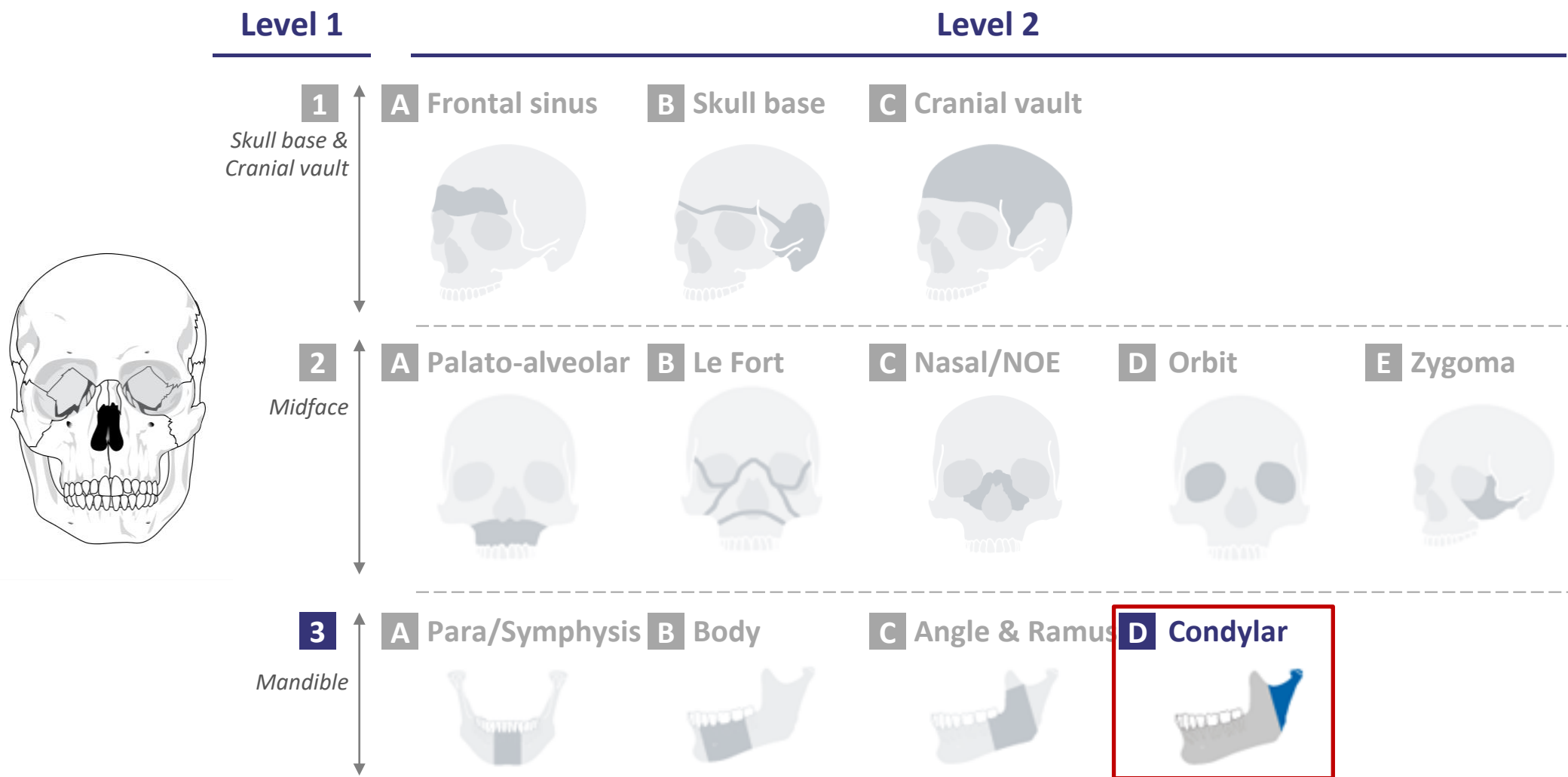
Sex: m

Age: 76

BMI: 23

18/07/2018

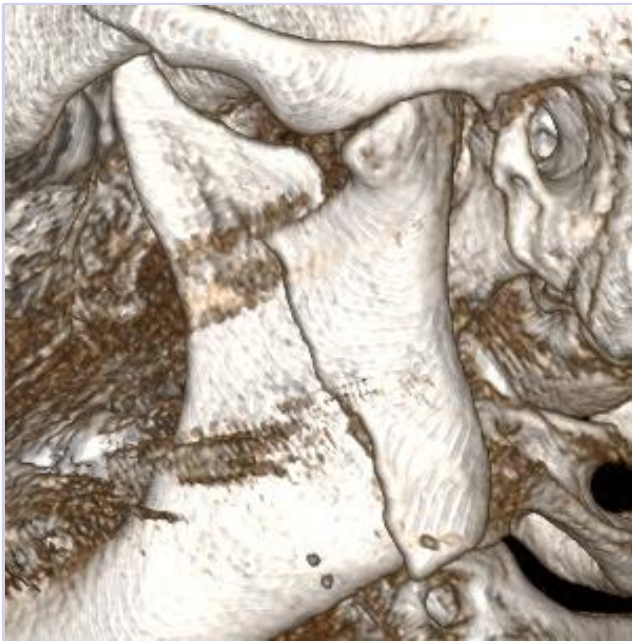
CMF fracture portfolio: 3D-Condylar





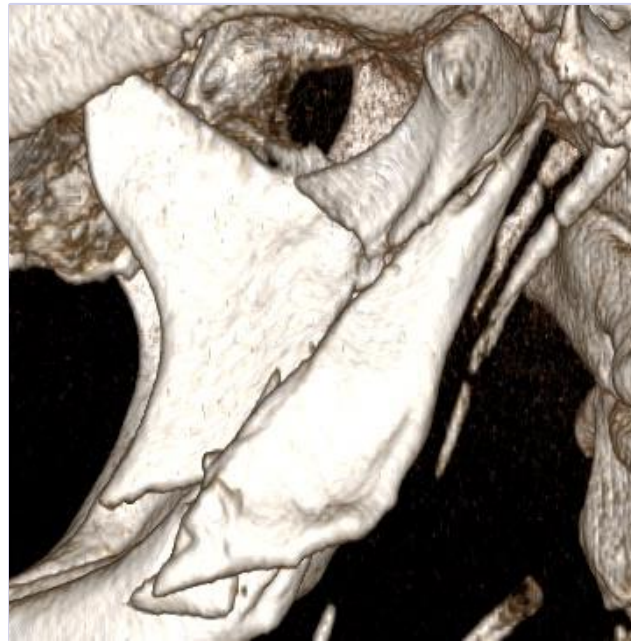level of complexity

Moderate



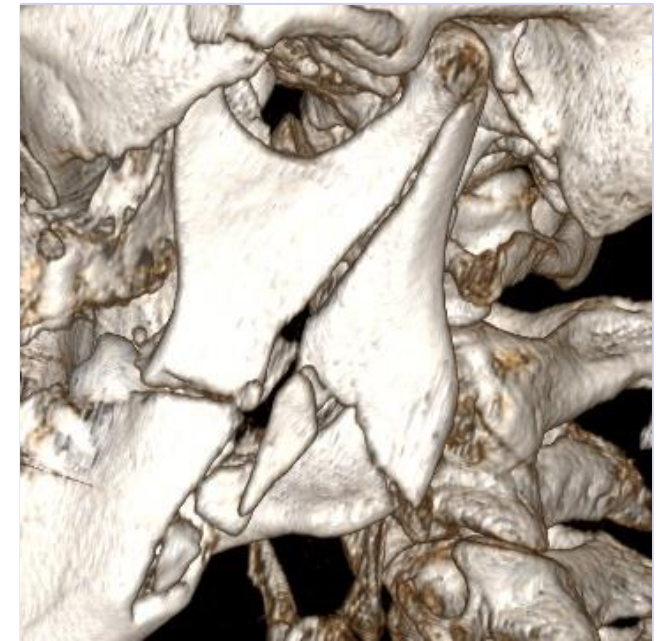
- Example: F180616

Advanced

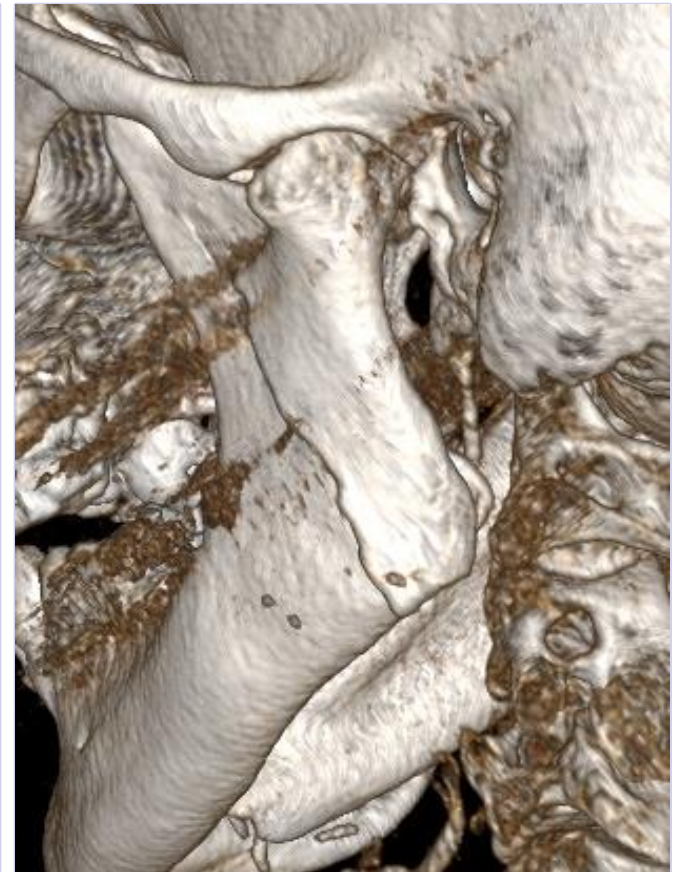
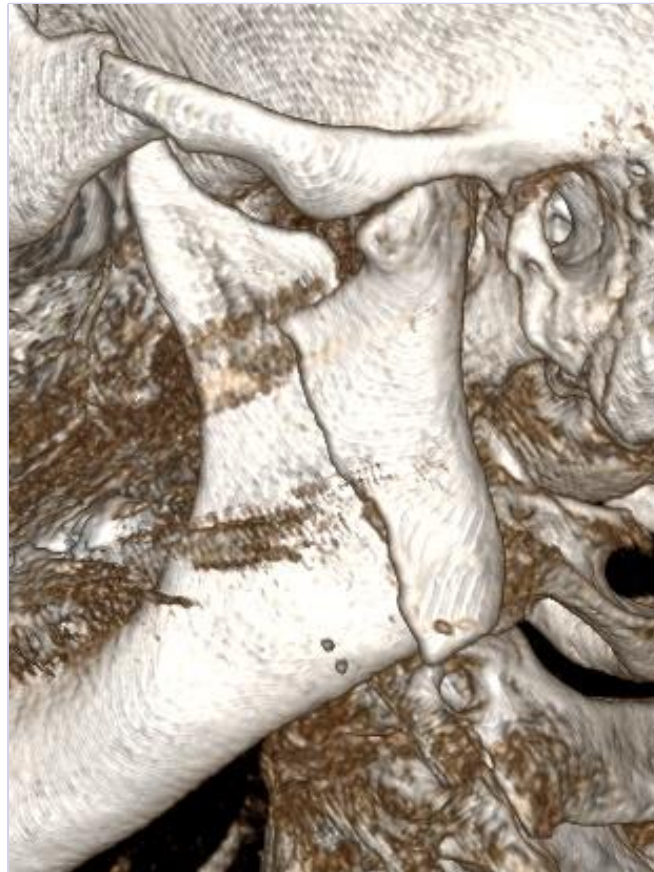
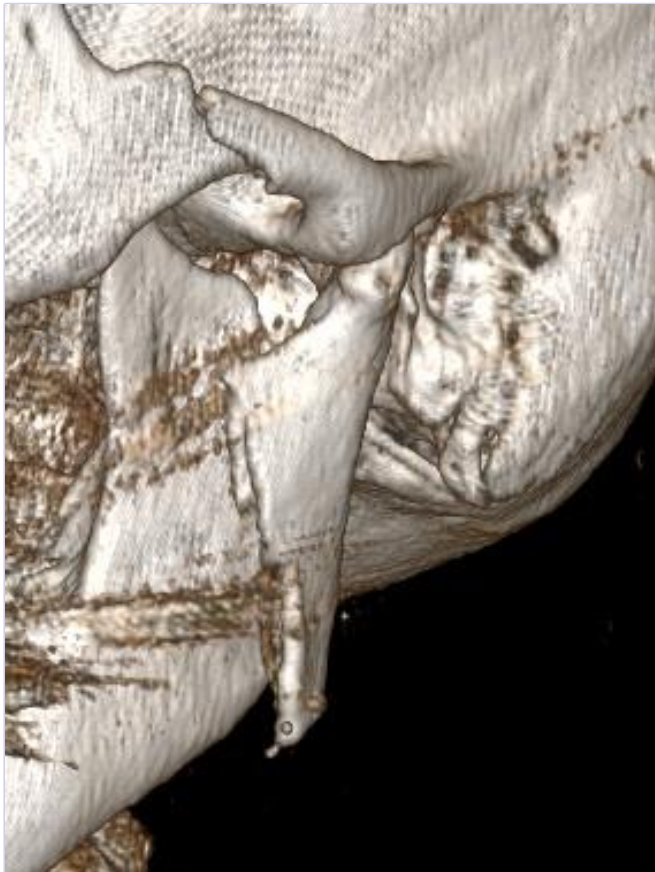

- Example: 1703249M

Master



- Example: 1603315M

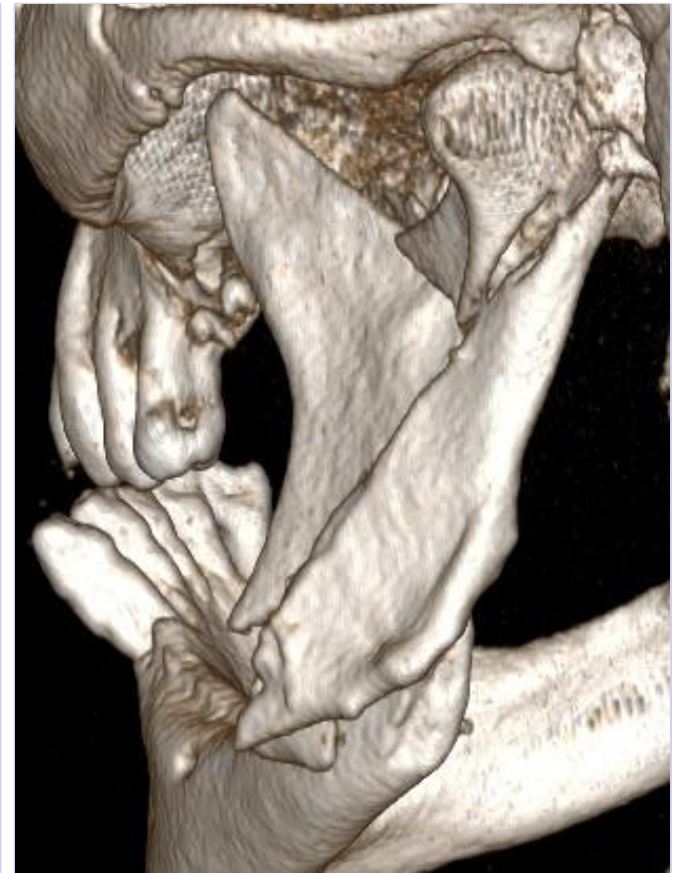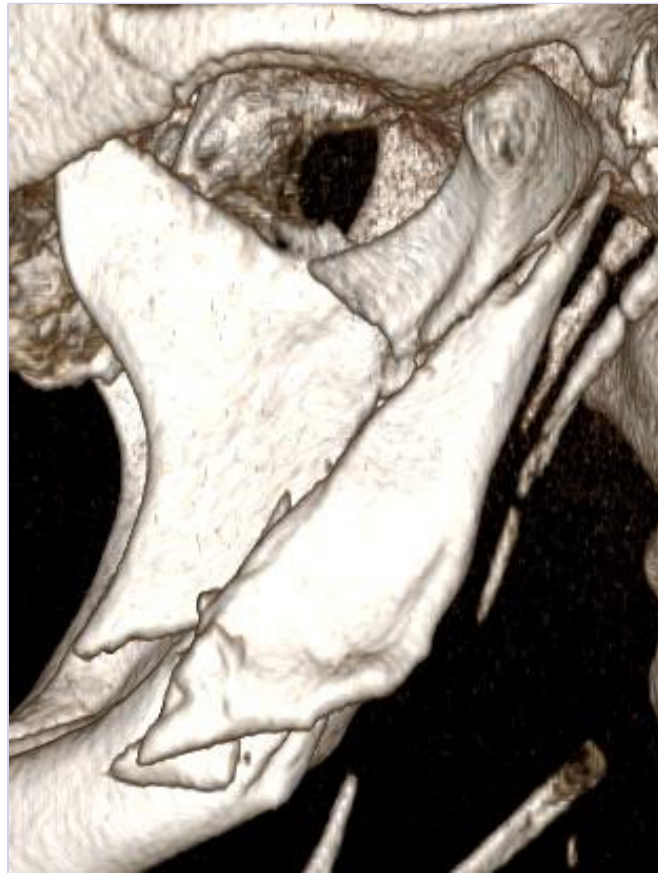

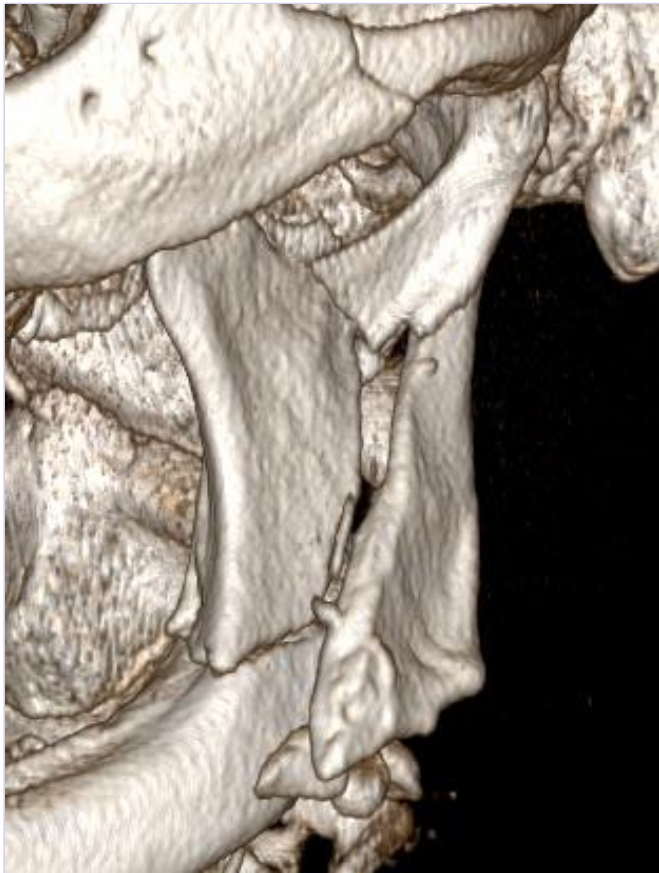
Sex: f

Age: 71

BMI: 20

18/07/2018

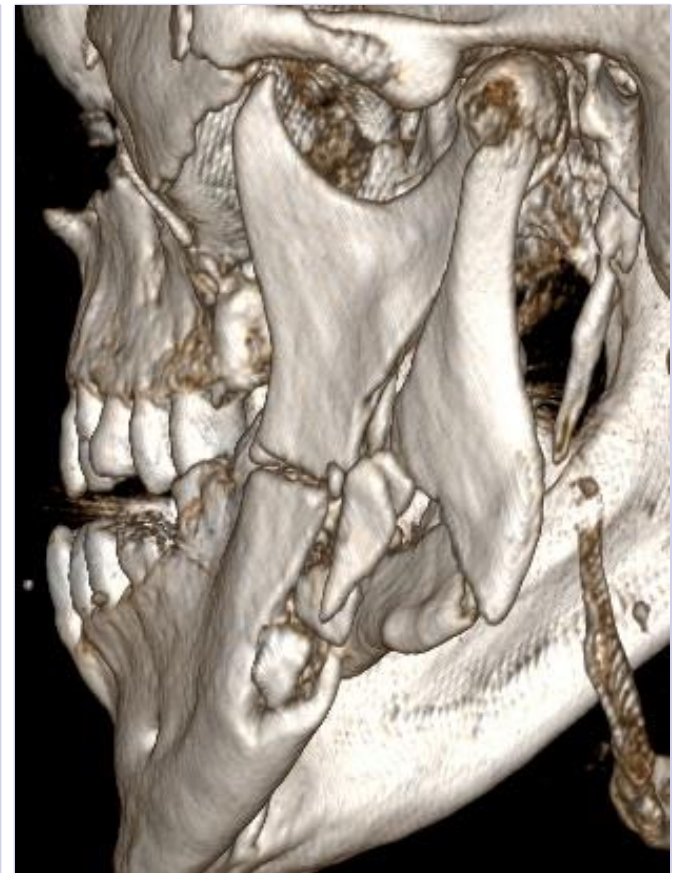
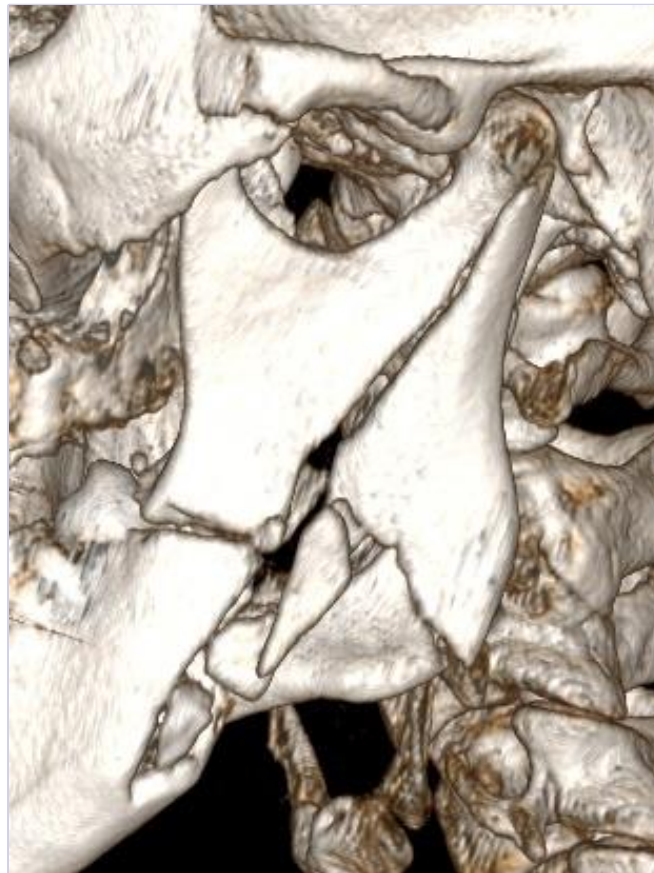
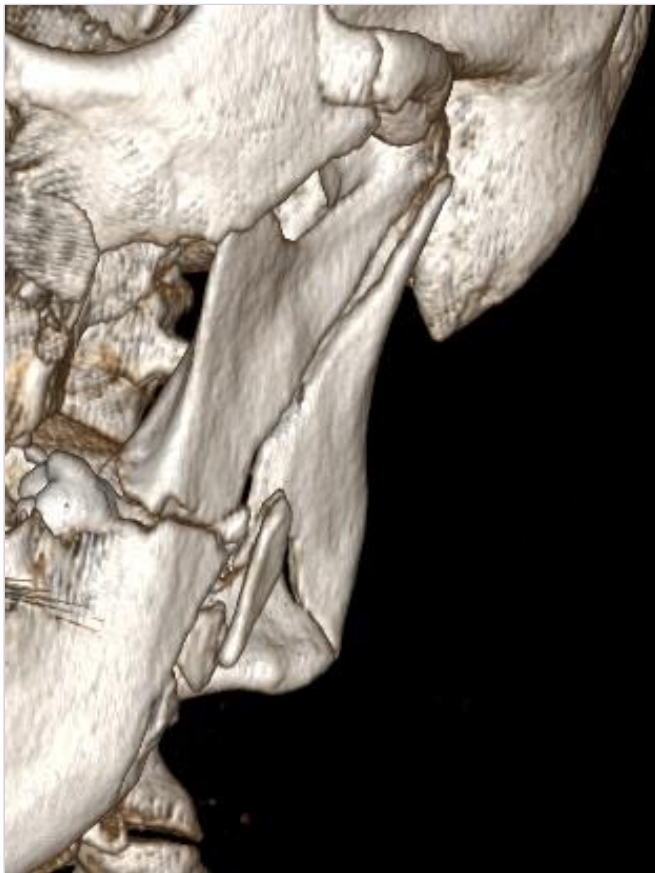Sex: m

Age: 48

BMI: 38

18/07/2018



Sex: m

Age: 37

BMI: 40

18/07/2018

RIMASYS REINVENT
SURGICAL
EDUCATION

RIMASYS GmbH
Nattermannallee 1
D-50829 Cologne
GERMANY

Mail: info@rimasys.com

Managing director: Marc Ebinger, Robert Holz

Explore more at www.rimasys.com